

POSITION PAPER

Magnetic resonance imaging in individuals with cardiovascular implantable electronic devices

Ariel Roguin^{1*}, Juerg Schwitter², Christian Vahlhaus³, Massimo Lombardi⁴, Josep Brugada⁵, Panos Vardas⁶, Angelo Auricchio⁷, Silvia Priori⁸, and Torsten Sommer⁹

¹Department of Cardiology, Rambam Medical Center, B. Rappaport-Faculty of Medicine, Technion-Israel Institute of Technology, Bat Galim, PO Box 9602, Haifa 31096, Israel; ²Division of Cardiology, Department of International Medicine (DIM), University Hospital Zürich, Zürich, Switzerland; ³Department of Cardiology and Angiology, Hospital of the University of Münster, Münster, Germany; ⁴MRI Laboratory, C.N.R., Clinical Physiology Institute, Pisa, Italy; ⁵Arrhythmia Section, Cardiovascular Institute Hospital Clinic, University of Barcelona, Barcelona, Spain; ⁶Cardiology Department, Heraklion University Hospital, Heraklion Crete, Greece; ⁷Division of Cardiology, Fondazione Cardiocentro Ticino, Lugano, Switzerland; ⁸Molecular Cardiology, IRCCS Salvatore Maugeri Foundation, University of Pavia, Pavia, Italy; and ⁹Cardiovascular Imaging Section, Department of Radiology, University of Bonn, Bonn, Germany

Received 24 December 2007; accepted after revision 7 January 2008

KEYWORDS

Imaging;
MR imaging;
Safety;
Pacemaker;
ICD

Magnetic resonance (MR) imaging has unparalleled soft-tissue imaging capabilities. The presence of devices such as pacemakers and implantable cardioverter-defibrillators (ICDs), however, was historically considered a contraindication to MR imaging. We summarize the potential hazards of the device-MR environment interaction, and present updated information regarding *in vitro* and *in vivo* experiments suggesting that certain pacemaker and ICD systems may indeed be MR-safe. Recent reports on several hundred patients with implantable pacemakers and ICDs who underwent MR scan safely indicate that, under certain conditions, individuals with these implanted systems may benefit from MR imaging. We believe that, on a case-by-case basis, the diagnostic benefit from MR imaging outweighs the presumed risks for some pacemaker and ICD patients. Thus for some patients, the risks presented by MR imaging under specific, characterized scanning and monitoring conditions may be acceptable given the diagnostic benefit of this powerful imaging modality. This may have major clinical implications on current imaging practice. A strategy for the performance of MR imaging in these individuals is proposed.

Introduction

Magnetic resonance (MR) imaging is a diagnostic technique used to obtain high quality images of the human body. The structure and abundance of water in the different tissues of the human body is the key to clinical MR imaging. The basic concept of MR is the absorption and emission of electromagnetic energy by atomic nuclei in a magnetic field after excitation by a radiofrequency (RF) pulse.^{1–3} A powerful magnet generates a magnetic field roughly 50 000 times

stronger than the natural background magnetism from the earth. Various types of clinical MR systems currently use the superconductive magnet which utilizes 0.5–3.0 T.

Unlike conventional radiography and computed tomographic imaging, which makes use of potentially harmful radiation (X-rays), MR imaging has many advantages, including its non-ionizing nature and the unparalleled ability to discriminate different soft tissues without iodinated contrast media. MR imaging has now become the modality of choice for imaging the brain, spinal cord, musculoskeletal system, head and neck, complex congenital heart malformations and other tissue structures.³ More recently, MR imaging has been applied successfully to evaluate myocardial structure, wall motion, perfusion, and viability. The number of MR

* Corresponding author. Tel: +972 4 854 2181; Fax: +972 4 854 3451.
E-mail address: aroguin@technion.ac.il

[†]A Position Paper from European Heart Rhythm Association and Working Group on Cardiovascular Magnetic Resonance of the European Society of Cardiology (EuroCMR).

scans performed annually has increased dramatically over the past few years.³⁻⁶

The growing problem

Parallel to the growth and evolution of the MR field, is the burgeoning number of patients benefiting from cardiovascular implantable electronic devices (CIEDs)-pacemaker, cardiac resynchronization therapy device, implantable cardioverter-defibrillator, implantable cardiovascular monitors and implantable loop recorders (Figure 1). With the growing proportion of the elderly population, new indications for heart failure therapy, innovative device features, and expanded medical coverage; this trend is likely to continue its trajectory.

The combination of these growing phenomena results in an estimated 50-75% probability of a patient being indicated for an MR study over the lifetime of their device, creating an estimated 200 000 cardiac device patients who were denied the MR scan and more in the future.^{7,8}

Given the rapid expansion of technology in the fields of both MR imaging and devices for arrhythmia and/or heart failure management, there is increasing interest in the issue of implantable device safety in the MR environment. Currently, no CIEDs have Food and Drug Administration (FDA) approval for use in the MR environment and 'Do not use MR imaging on patients who have an implanted device' appears on product labels.⁸ The current state of affairs significantly limits the performance of MR imaging on device patients.

With a better understanding of the hazards of performing MR scans on device patients as well as the development of MR-safe devices, we may soon enter an era where the ability of this imaging modality may be more widely used to assist in the appropriate diagnosis of patients with devices. Not only for heart imaging, but also mainly for brain, spine, and joints as knees and shoulders.^{1,7}

Hazards and safety concerns

Permanent cardiac pacemakers have historically represented a contraindication to MR imaging. Strong static, gradient, and RF fields used to create the MR image, can be detrimental to pacemaker function and potentially cause harm to patients undergoing MR examinations. The multiple potential adverse interactions between pacemakers and MR imaging^{1,2,9-12} include heating, rapid atrial pacing, pacing at multiples of the RF pulse, and associated rapid ventricular pacing, reed switch malfunction, asynchronous pacing, inhibition of pacing output, alteration of

programming with potential damage to the pacemaker circuitry or movement of the device and the potential of thermal injury at the lead tip (Table 1).

Support to this contraindication came from several reported lethal consequences of MR imaging in patients with implanted pacemakers.¹³⁻¹⁵ During the late 1980s, incidentally 10 deaths have been attributed to MR procedures in patients with pacemakers. However, these fatalities were poorly characterized and no electrocardiographic data were available. Irnich *et al.*,¹⁶ searched for all fatalities that occurred during MR investigation and reported by the Legal Medicine Departments in Germany. Between 1992 and 2001, six fatal cases occurred for which the German public prosecutor had ordered an autopsy. All six patients were examined in private radiology practices for orthopaedic or neurological reasons. The indication for pacemaker implantation was sick-sinus-syndrome and none was pacemaker-dependent. Unfortunately, all were without any monitoring during the scan, thus the death cause is problematic. It was determined as probably VF in three cases. In the other cases the death cause was unknown, though magnet rate was 100/min, which was according to the authors, in combination with tachycardia-bradycardia syndrome, suspected to have induced fibrillation. Worldwide, no deaths have been reported during physician-supervised MR procedures in the last decade.

Despite the above-mentioned concerns, the interpretation of the MR effects on cardiac pacemakers remain controversial. Most of the previous studies that prohibit MR in pacemaker patients were based on *in vitro* and animal model data in the 1980s using older pacemaker and lead technology. During the last decade, several reports described small series¹⁷⁻²² of pacemaker patients who have safely undergone MR scanning (Table 2). Advances in device technology drove extensive, and seminal *in vitro* and animal studies of the pacemaker and ICD systems interaction with the MR, and in recent years, several groups scanned larger number of patients safely.²³⁻³⁶

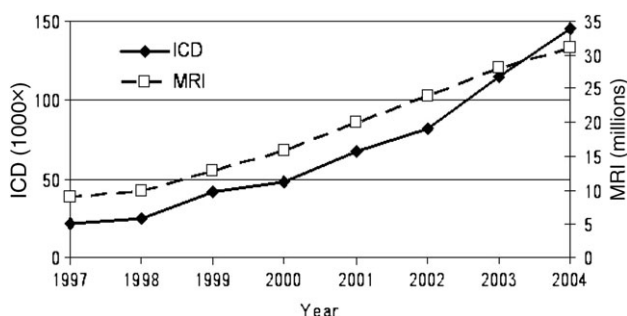


Figure 1 Number of annual magnetic resonance scans and of newly implanted implantable cardioverter-defibrillators in USA.

Table 1 Potential effects of magnetic resonance imaging on pacemaker, cardiac resynchronization therapy device, implantable cardioverter-defibrillator, implantable cardiovascular monitors and implantable loop recorders

- (1) Static magnetic field
 - Mechanical forces on ferromagnetic components
 - Unpredictable magnetic sensor activation, reed-switch closure
 - Changes in electrocardiograms
- (2) Modulated radio frequency (RF) field
 - Heating of cardiac tissue adjacent to lead electrodes
 - Possible induction of life-threatening arrhythmias (very rare)
 - Pacemaker reprogramming or reset
 - RF interactions with the device (over- and under-sensing)
- (3) Gradient magnetic field
 - Possible induction of life-threatening arrhythmias (unlikely in bipolar mode)
 - Induced voltages on leads cause over- and under-sensing
- (4) Combined field effects
 - Alteration of device function because of EMI
 - Mechanical forces (vibration)
 - Electronic reset of device
 - Damage to pacemaker/ICD and/or leads

Pacemakers are switched either to asynchronous magnet or interference mode, ICD therapy is switched off and interference mode does not exist.

Table 2 Published reports (1989–1998) describing the non-lethal consequences of magnetic resonance imaging in pacemaker patients

Author	<i>n</i>	Indication for MR imaging	Pacemaker model	Dual-/single-chamber	Lead polarity	PM mode	Field strength (T)	Outcome after MR imaging
Alagona (1989) ¹⁷	1	Brain tumour	AFP	Dual	Unipolar	OOO	1.5	Normal
Inbar (1993) ¹⁸	1	Cerebellopontine syndrome	Paragon II	Dual	Bipolar	OOO	1.5	Normal
Gimbel (1996) ¹⁹	1	Heart valve	AFP	Single	Unipolar	OOO	1.5	Image artifact
Fontaine (1998) ²⁰	1	Brain tumour	Genesis	Dual	Unipolar	DOO	0.5	Pause (2s)
	1	CIA	Paragon II	Dual	Bipolar	OOO	0.35	Normal
	1	Pituitary tumour	Synchrony	Dual	Bipolar	DOO	1.5	Normal
	1	Cervical disc	Synchrony II	Dual	Bipolar	DDD	1.0	Normal
	1	Dizziness	Thera DR	Dual	Bipolar	VVI	1.5	Rapid vent pacing
Garcia Bolao (1998) ²¹	1	Cranial nerve palsy	Meta	Dual	Bipolar	AOO	1.0	Asynchronous pacing
Sommer (1998) ²²	18	CNS	Elite	Dual	NA	DOO	0.5	Asynchronous pacing
		Cardiac tumour	Elite	Dual	NA	DOO	0.5	Asynchronous pacing
		Periprosthetic (asc.aorta)	Elite	Dual	NA	DOO	0.5	Asynchronous pacing
		Pseudoaneurysm	Relay	Dual	NA	VOO	0.5	Normal
		Paravalvar Prosth	Vista	Dual	NA	DDD	0.5	Asynchronous pacing
		Constrictive pericarditis	Dialog	Single	NA	VVI	0.5	Asynchronous pacing

n, number of patients studied; NA, data not available; PM, pacemaker; T, Tesla.

In vitro and animal studies

Device function

Early reports (1980s–mid-1990s)

The potential hazardous effects of MR imaging in patients with cardiac pacemakers have been studied since 1983. Pavlicek *et al.*¹¹ postulated that RF fields present in an MR unit could possibly inhibit demand pacemakers and time-varying magnetic fields could generate pulse amplitudes to mimic cardiac activity. The threshold for initiating the asynchronous mode of a pacemaker was reported to be as low as 17 Gauss (1 Gauss = 10⁻⁴ T). Other groups reported that thresholds varied between 0.72 and 6.15 mT, mean value being 1.58 mT (*n* = 383). Of note, the reed switch can stay 'open' at higher field strength as well. Fetter *et al.*¹² showed that pacemakers reverted from the demand to the asynchronous mode within the magnetic field of the scanner (0.15 T). Microscopic testing showed no evidence of reed switch sticking or magnetizing, or damage to other discrete pacemaker components. Erlebacher *et al.* tested different DDD pacemakers (currently not in use) in a saline phantom, and showed that during scanning at 0.5 T, RF interference caused total inhibition of atrial and ventricular output, or resulted in atrial pacing at very high rates.⁹ The potential for rapid cardiac stimulation during MR was also reported in animal studies.²³ Lauck *et al.* investigated the performance of different stimulation modes (VVI, VVIR, VOO, DDD, DDDR and DOO) during MR scan at 0.5 T.²⁴ Reversible activation of the reed switch with consecutive asynchronous stimulation was observed in all pacemakers. Pacemakers in the asynchronous mode were not affected

with regard to stimulation rate and capture during scanning. In contrast, pacemakers with automatic mode switching to demand pacing or programmed inactivation of the reed switch were triggered in the dual-chamber mode and were inhibited in the single-chamber mode. Thus, the investigators recommended programming into the asynchronous mode prior to scanning on 0.5 T, and in those without permanent pacemaker dependency, complete inactivation of the system, if possible.

The effects of more powerful MR scanners (i.e. 1.5 T) on cardiac pacemakers were initially reported by Hayes *et al.*²⁵ *In vivo* evaluation of different single- and dual-chamber pacemakers showed reversion into asynchronous mode and transient reed switch activation. Seven of the eight pulse generators paced rapidly when exposed to the RF signal associated with a marked decrease in blood pressure. Stimulation cycle length was 200 ms (300 bpm) corresponding to the frequency of scan pulsing. It was proposed that rapid pacing was the result of an 'antenna' effect that couples the RF energy back into the pacemaker output circuits.

Recent reports (mid 1990s–today)

Importantly, most of the above were reports on earlier generation pacemakers, most likely currently not in use any more. Recent reports^{26–29} testing improved technology devices found no functional issues in most pacemakers exposed to prolonged MR scan.

Achenbach *et al.*²⁶ showed in a phantom study on 11 pacemakers and 25 leads that no pacemaker malfunction was observed in asynchronous pacing mode (VOO/DOO),

whereas inhibition and rapid pacing were observed during spin-echo imaging if the pacemakers were set to VVI or DDD mode. The authors suggested that rapid pacing was caused by induction of currents above sensing threshold in the atrial lead and consequent triggering of ventricular stimulation. Direct interference with the pacemaker electronics seemed to be an unlikely explanation, because the rapid pacing rate was always equal to the programmed frequency limit.

Heat

Measuring lead heat in the MR environment may be challenging, is technically difficult and depends on the methods used; explaining why several groups report different results.

In vitro

Achenbach *et al.*²⁶ investigated the heating effect of pacemaker leads using *in vitro* continuous registration of the temperature at the lead tip with an optical temperature sensor, recorded a maximal temperature increase of 63.1°C during 90 s of scanning. In seven electrodes, the temperature increase exceeded 15°C. Sommer *et al.*²² found *in vitro* that the maximum temperature increase depends on specific absorption rate (SAR) with 8.9°C at 0.6 W/kg and 23.5°C under a worst case RF heating condition with an SAR of 1.3 W/kg. Roguin *et al.*²⁷ using a maximal energy protocol SAR of 3.7 W/kg found *in vitro*, maximal heating of 7°C.

In vivo

Roguin *et al.*²⁷ found *in vivo*, when the leads were inserted into the right ventricle of a canine model, that there was almost no rise in temperature. This was probably because of the blood flow and heat dissipation. More importantly, a chronic animal model of 15 dogs who had ICD leads implanted and all scanned during prolonged (3–4 h) MR scans, including high energy MR protocols (SAR of 4 W/kg)—revealed no heat-induced injury. No tissue damage was also recently reported by Schmiedel *et al.*²⁸

Luechinger *et al.*²⁹ used pacemaker leads with additional thermocouple wires as temperature sensors implanted in nine animals to measure heating. They recorded temperature increases of up to 20°C during MR imaging of the heart. However, *in vivo*, they found only minor stimulation threshold changes (<0.5 V) and no pathology and histology heat-induced damage. Of note, the authors stated that cell damage of implantation could not be distinguished from cell damage owing to heating.²⁹

Although Roguin *et al.*²⁷ in their *in vivo* study found no heat or pacing threshold change using optic-fibre measurements, yet using additional thermocouple wires, Luechinger *et al.*²⁹ found a significant temperature rise. Both studies were done in the presence of blood flow protection by the cooling effect of myocardial blood flow and perfusion. In spite of the different methods used, and the different heat measurements recorded, both groups reported only *minor* stimulation threshold changes and *no* clear heat-induced damage in histopathology.

We are cautious and state that concluding that heating of the electrode is not a real problem in MR scanning, should not be drawn. Some of the temperature increases, measured by different groups, using various methods are in a range

that is used for temperature-controlled RF catheter ablation of cardiac tissue ablation and this can theoretically induce tissue injury at the lead tips. Yet, three different groups recently reported no evidence for *in vivo* tissue injury^{27–29}.

What is the clinical human data regarding the potential of thermal injury to cause change in pacing threshold? While several patients' papers report no change,^{35,36} there are several groups which reported minor non-clinically significant changes in a small percentage of patients.^{32–34} In Sommer's recent study,³⁴ MR imaging-related troponin level increase as an indicator of thermal injury were found in 4 of 114 examinations, which in one case was associated with a 1.0 V increase in pacing capture threshold. In currently published papers there are no report of loss of pacing capture.

Force and torque

Several studies (at 1.5 T) found that the force in pacemakers was negligible around 0.05–3.6 N, and in ICDs it was 1–5.9 N depending on the year it was manufactured and the amount of ferromagnetic material used. Older devices (approved by the FDA prior to 1998) exert significant forces; however most newer ICDs exert only one-fifth of it.^{27,28,30,31}

In summary, for *in vitro* and *in vivo* data there are studies^{27,28,30}, which found minimal force induced by the pacemakers and no function problems with current generation devices. There was neither tissue damage observed^{27–29} nor pacing capture permanent failure suggesting that certain pacemakers and ICD systems may indeed be MR-safe.

Human studies

Reports using older technology (until late-1990s)

In the earliest years of MR, using early-generation pacemaker devices, as mentioned above, there were few anecdotal reports of unexpected deaths in patients undergoing MR imaging.^{13–15} In one case, the patient had no escape from ventricular rhythm and apparently died because of asystole. Another patient developed ventricular fibrillation during the imaging procedure that was not recognized immediately because ECG monitoring was not used.³¹ On the other hand, there were several reports of pacemaker patients who underwent MR imaging safely (Table 2).

In patients who underwent MR imaging of the head, no pacemaker malfunction was observed with the pacemaker turned off or programmed to an asynchronous pacing mode prior to MR exposure.^{17–21} In another study on five patients with pacemakers, Gimbel *et al.* reported normal pacemaker performance in four patients during MR (0.35 and 1.5 T).¹⁹ One patient had paused for approximately 2 s duration. No rapid cardiac pacing occurred and no patient reported a torque or heating sensation. Fontaine *et al.* reported a case of rapid cardiac pacing during MR imaging (1.5 T) in a patient with a dual-chamber pacemaker.²⁰ The patient developed an irregular ventricular rhythm during RF pulsing which terminated with the cessation of RF pulsing. Sommer *et al.* showed in a prospective study, with 44 pacemaker patients undergoing MR imaging at 0.5 T with an upper SAR limit of 0.6 W/kg, that atrial and ventricular thresholds stimulation thresholds, P and R wave amplitudes, electrode impedance, battery voltage, -current, and

-impedance, remained unchanged immediately after MR imaging and at 3-months follow-up.²²

Reports using present technology

Vahlhaus *et al.*³² were among the first who conducted a follow-up study. Their experience using 0.5 T MR system on 34 MR examinations in 32 patients with implanted pacemakers included a complete pacemaker check at 3 months. They concluded that MR imaging at 0.5 T does not cause irreversible changes in pacemaker systems neither immediately following MRI nor 3 months later. Lead impedance, sensing and stimulation thresholds did not change when compared with baseline. Battery voltage decreased immediately after MR imaging and recovered 3 months later. Reed switch behaviour was analyzed systematically revealing that activation of the reed switch by the static magnetic field is not predictable.

In a recent study³³, 54 non-pacemaker-dependent patients, underwent 64 MR examinations at 1.5 T. Of note, 9.4% of the leads underwent statistically significant threshold changes but not clinically, and were easily addressed with subtle programming changes. Patients' symptoms and electrographic changes were mild and transient and did not warrant cessation of MR scan.

Schmiedel *et al.*²⁸ tested in brain MR scans, the translational forces and temperature increase (max < 2.98°C) that were in a range, which does not represent a safety concern from a biophysical point of view. They reported their experience with 63 MR imaging examinations at 1.5 T in 45 patients with implanted pacemakers. Prior to MR the devices were reprogrammed to an asynchronous mode. The maximum SAR of MR sequences was limited to 1.2 W/kg. Continuous monitoring of ECG and pulse oximetry was performed during MR imaging. No changes to the programmed parameters of the pacemakers or damage of device components were observed neither *in vitro* ($n = 0/24$) nor *in vivo* ($n = 0/63$). All patient studies (brain MR) ($n = 63/63$) could be completed without any complications. Atrial and ventricular stimulation thresholds neither did change significantly (<1.0 V) immediately post-MR imaging nor in the 3 months follow-up.

Sommer *et al.*,³⁴ in the largest series published so far, report on 82 pacemaker patients who underwent a total of 115 MR imaging examinations at 1.5 T. All devices were from a single manufacturer (Medtronic). Inclusion criterion was urgent clinical need for an MR imaging examination. Pacemaker-dependent patients and those requiring examinations of the thoracic region were excluded. The SAR was limited to 1.5 W/kg. This study assessed post-MR imaging pacemaker function, measured troponin levels as an indicator of thermal injury, and followed short-term outcome. All pacemakers were reprogrammed before MR imaging: If heart rate was <60 bpm, the asynchronous mode was programmed to avoid MR-induced inhibition; if heart rate was >60 bpm, sense-only mode was used to avoid MR-induced competitive pacing and potential proarrhythmia. Patients were monitored with ECG and pulse oximetry. All pacemakers were interrogated immediately before and after the MR imaging examination and after 3 months, including measurement of pacing capture threshold and serum troponin I. All MR examinations were completed safely. Inhibition of pacemaker output or induction of arrhythmias was not

observed. Pacing capture threshold increased significantly from pre- to post-MR imaging ($P = 0.017$). In 2 of 195 leads, an increase in pacing capture threshold (of 1.0 V at pulse duration of 0.4 ms) was detected only at follow-up. In 4 of 114 examinations, troponin increased from a normal baseline value to above normal after MR imaging, and in one case (troponin pre-MR imaging, 0.02 ng/mL; post-MR imaging, 0.16 ng/mL), this increase was also associated with a 1.0 V increase in pacing capture threshold (from 0.5 to 1.5 V).

Nazarian *et al.*³⁵ reported on 55 patients who underwent 68 MR imaging studies, 31 had a pacemaker, and 24 had an ICD (the largest series reporting on ICD systems). Patients with no imaging alternative and with devices shown to be MR imaging-safe by *in vitro* phantom and *in vivo* animal testing were enrolled.²⁷ They concluded that given appropriate precautions, non-cardiac and cardiac MR imaging can potentially be safely performed in patients with selected implantable pacemaker and defibrillator systems.³⁵ Pacing mode was programmed to 'asynchronous' for pacemaker-dependent patients and to 'demand' for others. Magnet response and tachyarrhythmia functions were disabled. Blood pressure, ECG, oximetry, and symptoms were monitored. Average SAR was <2.0 W/kg. No episodes of inappropriate inhibition or activation of pacing were observed. There were no significant differences between baseline and immediate or long-term (median 99 days after MR imaging) sensing amplitudes, lead impedances, or pacing thresholds (maximal capture change observed was <1.0 V). Diagnostic questions were answered in 100% of non-thoracic and 93% of thoracic studies. Clinical findings included diagnosis of vascular abnormalities (9 patients), diagnosis or staging of malignancy (9 patients), and assessment of cardiac viability (13 patients).

Magnetic resonance imaging in pacemaker-dependent patients

Little has been presented regarding MR imaging of pacemaker-dependent patients. Gimbel *et al.*³⁷ reported their experience of 10 pacemaker-dependent patients who underwent a total of 11 MR scans of the head and neck. Pacemakers were reprogrammed to asynchronous pacing (VOO or DOO at 60 bpm). A transmit-receive coil was used and MR pulse sequences were modified to limit whole-body SAR <2 W/kg. All scans proceeded uneventfully. No post-MR programming changes were noted. No patient experienced arrhythmia or symptoms during or immediately after MR imaging. Battery status remained unchanged. No patient experienced significant post-MR imaging or 3-month follow-up change in sensing or pacing thresholds (maximal capture change observed was <0.5 V). Safe inadvertent scanning of pacemaker-dependent patient also has been performed by Nazarian *et al.*³⁵ ($n = 12$) and Goldsher *et al.*³⁶ ($n = 3$).

These results suggest that also pacemaker-dependent patients may be offered MR if careful patient monitoring and pacemaker reprogramming is performed in concert with use of a transmit receive coil (in cranial scans) and implementation of specific MR sequences designed to limit power deposition over the device. A larger prospective series of pacemaker-dependent (and non-dependent)

patients needs to be evaluated before a benign outcome can be expected.

Safety issues in patients with retained pacing leads

Permanent leads

Many patients have endocardial pacemaker leads left in place after pulse generator removal. The safety of MR in patients with retained endocardial pacemaker wires has not been systematically investigated to date. However, there is a potential threat that they may act as 'antennas' with significant heating (even if the electrode has a cap). The heating of retained endocardial leads may be even higher when compared with normally connected leads. Although a potentially higher risk population, we feel that MR imaging may be considered with the precautions and follow-up measures in accordance with our recommendation for pacemaker patients.

Temporary pacing wires

Temporary pacing wires are usually made of stainless steel, sutured to the epicardial surface of the heart over the right ventricle and right atrium after cardiac surgery, and connected to an external pacemaker if the patient develops bradycardia or atrioventricular block.³⁸

Hartnell *et al.*³⁹ investigated the safety of 1 or 1.5 T MR systems operating with conventional pulse sequences in 51 patients by retaining epicardial pacing wires, cut short at the skin, after cardiac surgery. None of the patients reported symptoms suggesting arrhythmia or other cardiac dysfunction during MR imaging, and there were no changes from the baseline ECG rhythms. Therefore, retained epicardial wires may represent a minor risk to patients in the MR environment. However, this conclusion applies mostly to non-cardiac MR examinations.⁴⁰

Electrical reset in the MR environment

It is noteworthy that pacemakers can undergo an electrical reset.²⁷ An electrical reset is an emergency mode that represents a safety feature to guarantee minimal pacemaker functionality in case of battery voltage dips because of electromagnetic interference (EMI) or battery depletion. An electrical reset implies a change in the programmed parameters to factory default settings, usually an inhibited pacing mode (VVI) and activated tachycardia therapies in ICDs. Several publications³⁴ have demonstrated an incidence of 6.1% for an electrical reset.

This finding is important from a safety point of view for several reasons: (i) In the case of an electrical reset and an open reed switch, pacemaker output may be inhibited by the time-varying gradient fields, potentially leading to bradycardia/asystole in patients with low intrinsic heart rates;⁴¹ (ii) The default pacing mode and output may provide inadequate pacemaker functionality for a given patient: (a) In all pacemaker-dependent patients owing to potential inhibition of pacemaker output. (b) In children, who are known to have high intrinsic heart rates, the emergency VVI 65 mode after an electrical reset may not provide a sufficient cardiac output. (c) In patients requiring a high pacemaker output to ensure effective stimulation, the default output parameters after an electrical reset may not provide effective stimulation. (d) Pacemaker patients who also have an ICD. In these patients, the pacemaker

usually is inactivated to avoid undersensing of ventricular fibrillation as bradycardia by the pacemaker. In the case of an electrical reset with subsequent switch to VVI mode, the occurrence of ventricular fibrillation could result in pacemaker stimulation, which could lead to fatal inhibition of ICD therapy delivery. (e) In patients with an ICD, the deactivation of therapy delivery prior to MR imaging may be reactivated because of the electrical reset.

Up to date, it remains impossible to control these unwanted changes of device programmes, which again underlines the need for a close cooperation between Radiologist and Cardiologist and/or electrophysiologist and the necessity for having an advance cardiac life support (ACLS)-trained physician at the MR site.

Magnetic resonance imaging in patients with implantable cardioverter-defibrillators

Although different with respect to large capacitors and larger batteries that may cause higher magnetic forces, all CIEDs share similar components and thus, to some extent, their response to the EMI present during MR scanning may be expected to be similar.^{1,8,14} Despite dramatic reduction in size and weight, new generation ICDs have 10 times higher magnetic force and torque than pacemakers.

When tested, forces on older ICDs were 1–5.9 N on modern ICDs, 0.5–1.1 N when compared with 0.05–0.12 N in pacemakers.^{27,28} The implanted device has a fibrotic envelope around it several weeks after implantation. Forces <2 N will not be felt by the patients.²⁷ For all pacemakers and most modern ICDs, the measured acceleration was lower than the gravity of the earth (9.81 N/kg).²⁹

ICD devices may falsely detect the MR RF field as ventricular tachyarrhythmia (Figure 2), charge capacitors, and subsequently deliver antitachycardia pacing, cardioversion or defibrillation therapies. In addition, magnetic fields may prevent detection of ventricular tachycardia or fibrillation. The heating problem of ICD leads can be expected to be comparable with that of pacemaker leads.^{27,29}

Despite many pacemaker patients having reportedly undergone MR imaging using a variety of strategies to allow safe MR scanning, relatively little has been reported regarding ICD patients undergoing deliberate MR. Several case reports^{42–45} have described the ill effects of inadvertent MR imaging of ICD patients. Interestingly, the same devices were tested *in vitro* by Roguin *et al.*,²⁷ and the same findings were found—unable to interrogate these older generation ICDs.²⁷ One case report of an ICD patient inadvertently undergoing MR imaging noted a substantial rise in pacing thresholds subsequent to the MR exposure.⁴⁴

Naehle *et al.*⁴⁶ reported on an ICD patient safely undergoing MR scan of the brain using dedicated precaution measures such as limitation of SAR, inactivation of sensing function, and therapy options.

Concerns over a possible rise in defibrillation test (DFT) was recently answered by a recent preliminary report of ICD patients undergoing MR that showed greater than the 10-J safety margin post-MR imaging DFT testing.³³ No heart tissue thermal injury was found by Roguin *et al.* in 15 dogs that underwent prolonged MR scans—4 weeks after ICD implantation.²⁷

Recently, deliberate scanning of ICD patients was reported. Wollmann *et al.*⁴⁷ report on a patient with an

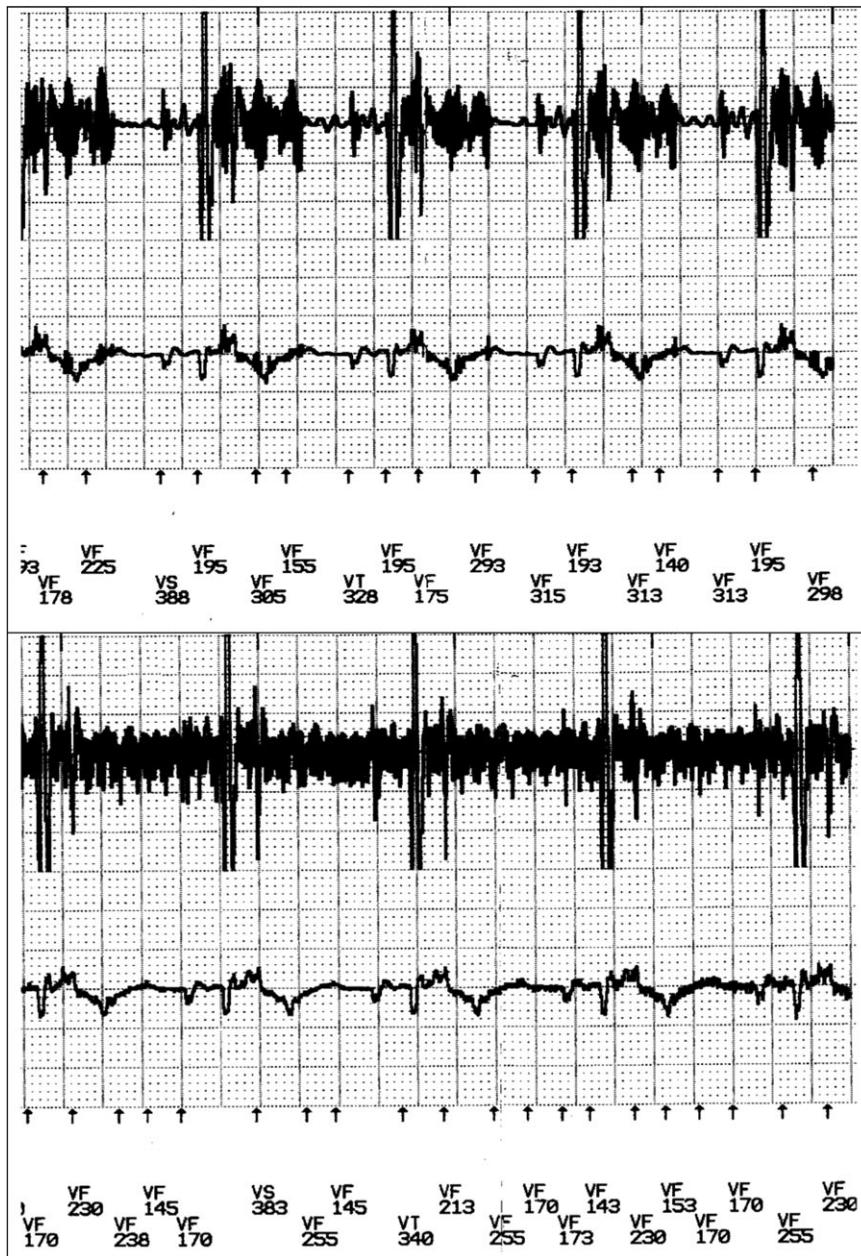


Figure 2 Magnetic resonance scan noise falsely detected by an ICD as ventricular fibrillation. (A) Magnetic resonance pulse (ECG-gated) sequence; (B) magnetic resonance continuous sequence.

ICD who intentionally underwent MR imaging of a malignant brain tumour for three times at 8-week intervals. The ICD was inactivated by programming the VT detection and VT/VF therapy status off. The patient came through the protocol safely and without any difficulty or discomfort. There was no arrhythmic event. MR imaging affected neither programmed data nor the function of the ICD system. This was the first study that confirmed the integrity and functionality of the ICD including an unchanged defibrillation threshold and the ability to correctly detect ventricular fibrillation. Roguin *et al.*,⁴⁸ based on their *in vitro* and *in vivo* results, implanted an ICD that was found (*in vitro* and *in vivo* experiments) to be safe, in a young patient with ventricular arrhythmia and suspected arrhythmogenic right ventricular dysplasia (ARVD). To confirm the diagnosis, a follow-up MR scan was advised. So the patient underwent

intentional MR imaging 6 weeks after implantation. The scan was safe and most of the MR images were of high quality.

Gimbel *et al.*⁴⁹ reported their experience on seven ICD patients who underwent eight MR imaging scans at 1.5 T. Post-MR scan, all devices demonstrated no change in pacing, sensing, impedances, charge times, or battery status. None of the patients had any discomfort. They concluded that scanning of ICD patients might be performed if appropriate reprogramming and monitoring was implemented.

Nazarian *et al.*,³⁵ report on the largest series of patients with ICDs who had MR imaging. They scanned 24 patients with ICDs and 7 with biventricular pacing systems and reported that all were safely scanned.

Theoretical physical considerations imply that therapy delivery by an ICD while being in the static magnetic may

not be possible, yet evidence for this inability is still not available. These considerations are based on the facts that the transformer within the ICD will be magnetically saturated because of the static magnetic field of the MR system, thus being incapable to provide the voltage necessary to charge the capacitor. However, this may lead to permanent device failure, as some devices become permanently inactive after a given number of unsuccessful attempts to charge the capacitor. Therefore, deactivation of therapy delivery is mandatory prior to MR imaging. Still, a residual risk remains because of the possible occurrence of an electrical reset with subsequent therapy activation.

The rapidly accumulating number of complication-free scanned patients with pacemakers directs one to surmise that we may also safely scan patients with ICDs if similar strategies that had allowed safe MR in pacemaker patients were applied to ICD patients. Some investigators^{27,50} have suggested that 'modern' devices are less prone to the effects of MR and because of better built-in EMI protection circuitry. Disabling the tachyarrhythmia detection and therapy is one strategy that has been recommended. Programming to therapy off avoids delivering therapy as a result of interpretation of noise as tachyarrhythmia.²⁷

Magnetic resonance image quality and magnetic resonance compatibility definitions

Individuals with implanted devices are referred to MR imaging for a specific clinical question. If a high quality image cannot be obtained, there is no purpose in exposing these people to the test. Devices can be (i) fully MR imaging-compatible (function appropriately and without significant image distortion) or (ii) MR-safe (function appropriately in the MR environment but distort the image) or (iii) may not be usable in an MR scanner.^{50,51}

The American Society for Testing and Materials (ASTM) offered a slightly different classification: (i) MR-safe: an item that poses no known hazards in all MR environments. (ii) MR Conditional: an item that has been demonstrated to pose no known hazards in a specified MR environment with specified conditions of use. The item labelling should include results of testing sufficient to characterize the behaviour of the item in the MR environment. In particular, testing for items that may be placed in the MR environment should address magnetically induced displacement force and torque, RF heating, and function. Any parameter that affects the safety of the item should be listed and any condition that is known to produce an unsafe condition must be described. And (iii) MR-unsafe: an item that is known to pose hazards in all MR environments.

Image artefacts and RF noise can be caused by the presence of implanted devices in the MR environment which are in or near the imaging field of view (such as implants or surface electrodes). These materials produce their own characteristic static magnetic field that can perturb the relationship between position and frequency essential to accurate image reconstruction. If the object has a magnetic susceptibility that is significantly different from that of tissue, distortion will result. Primary concerns with image artefact and noise include the production of a signal void where anatomical information is needed as well as the production of artefacts that may be misdiagnosed as pathology.

Schueler *et al.*⁵¹ have offered an assessment of image quality according to four criteria: geometric distortion; susceptibility-induced artefact; warping artefact; and bending, warping, or obliteration of image contours. Most artefacts from pacemakers and leads result in local image distortion, signal voids, or increased noise.

In an *in vivo* study²⁷ in a dog model using the clinical scanning protocols, image distortion was analyzed by measuring the area where there was a void in the MR image. Image distortion was dependent on scan protocol and image plane: fast spin echo and steady-state free-precession sequences had significant distortion. Fast-Gradient Recalled Echo, Tagging and Fast-Spoiled Gradient Recalled Echo sequences, however, yielded good images. Larger artefacts were observed in image planes roughly parallel to the planes defined by the device itself. Most distortions were at a distance of 10–15 cm around the device generator. The authors concluded that image distortion was dependent on the imaging plane and protocol used. Most image distortion was in the area adjacent to the device generator. Therefore, organs visualization beyond this distance, such as knees, lower spine, liver or brain, will most likely not be affected by the presence of the pacemaker or ICD.

Discussion

Most researchers in the field agree that although several hundreds of patients with implanted devices underwent safe MR scan—this does not allow to conclude that MR imaging in patients with pacemakers or ICDs is indeed safe. We acknowledge the limitations that prevent extending these encouraging results to recommendations for routine use of MR imaging in patients with pacemaker and ICD systems. According to the FDA's definition,⁵² today's pacemaker and ICDs are neither 'MR-safe' nor 'MR-compatible'. Because of the small size of the series and limitation of few manufacturers, given the range of available MR systems and scan conditions, pacemaker and ICD systems and leads, and the range of potential patient conditions, one cannot conclude that MR imaging can deliberately be performed routinely in pacemaker/ICD patients without risk.

Extending MR imaging use to the general pacemaker and ICD patient population through removal or modification of device warnings and contraindications will require further study to better understand the interaction between devices and MR imaging. To mitigate safety concerns such as heating, arrhythmogenesis, and proper device function, a thorough characterization and validation of the measures taken is required.

In 2004, the American College of Radiology (ACR) issued an update of its 2001 MR-Safe Practices Guidelines⁸ in which they reiterated their recommendation that implantable devices should be a contraindication for MR imaging. They added, however, that decisions for exceptions should be made on a case-by-case basis and that all MR scans should be performed under the guidance of both experienced radiologist and cardiologist/electrophysiologist, but noted that 'the expertise necessary to safely do so is exceedingly rare throughout the MR industry today'.

Tables 3 and 4 summarize our recommendations regarding MR imaging in patients with pacemakers or ICD systems. Should MR imaging be considered in an individual with an

implantable device, appropriate consultation with a qualified cardiologist is strongly advised so that patients can be adequately screened and correctable physiological abnormalities (e.g. hypoxia, electrolyte abnormalities, etc.) can be addressed prior to MR imaging. Special attention should be taken when the patient is pacemaker-

dependent. The clinician needs to document in the chart, that MR imaging is crucial for the management of the patient. No other imaging can be expected to provide an alternative or has been unsuccessfully tried. An informed consent form explaining the potential benefits and risks to the patient should be signed.

Table 3 Magnetic resonance imaging and pacemakers: safety concerns and guidelines

Patients are divided into three groups

(1) Pacemaker-dependent patients (very high risk)	If underlying rhythm is too slow—re-consider indication. The threshold for imaging and the safety requirements are higher, but no absolute contraindication
(2) ICD patient (non-dependent) ^a (high risk)	The patient must have a documented extremely serious, life threatening or severely quality-of-life limiting condition
(3) Pacemaker patient (non-dependent) (low risk)	The patient must have a documented very serious, life threatening or severely quality-of-life limiting condition

^aBecause of higher degree of interaction between MR imaging and ICD, the threshold for imaging is higher than for pacemakers.

Table 4 Technical aspects in magnetic resonance (MR) imaging of patients with pacemakers/implantable cardioverter defibrillators (ICD)

Arranging the procedure

Consensus of MR imaging-necessity without an imaging alternative by radiologist and cardiologist
 A cardiology consult must be obtained to determine pacemaker- or ICD-dependency
 If pacemaker-dependent—reconsider again the need for MR imaging
 Procedure must be approved by attending radiologist and cardiologist
 Procedure will be scheduled with Radiology and Cardiology in co-ordinated fashion
 MR imaging of pacemaker or ICD patients will only be performed in a main hospital
 If abandoned and/or epicardial leads are present, reconsider again the need for MR; minimize SAR, avoid thoracic region

Technical (MR imaging)

Field strength is limited to <1.5 T^a, limit SAR as much as possible. No SAR >2 W/kg body weight
 Minimize number and lengths of sequences
 Send/receive volume coils are preferred over surface coils

Technical (pacemaker/ICD)

Device must have been in place preferably for at least 4–8 weeks prior to MR imaging
 Cardiologist will be present for on-line analysis of cardiac rhythm
 Qualified personnel will perform a full device interrogation prior and immediately after MR scan
 Uninterrupted monitoring of ECG, blood pressure, breathing rate and oxygen saturation until threshold tests and reprogramming is performed following MR study
 Immediately prior to MR imaging, the pacemaker must be programmed to OFF; I.E. sensing (monitoring) only mode [0A0, 0V0, 0D0] or must be programmed to sub threshold outputs
 Lead polarity reprogrammed to bipolar if possible
 Additional diagnostic functions as magnet response, rate response, ventricular rate regulation, mode switch and capture management features will need to be disabled
 In cases that the patient is pacemaker-dependent, asynchronous mode should be programmed (V00, D00)
 ICD programmed to therapy off
 After completion of the MR study, re-interrogate device and lead parameters and reprogram to original settings
 Measure sensing-, pacing-, thresholds
 This should be done in the MR unit area preferably before ECG-monitoring is discontinued
 An interrogation of the pacemaker or ICD will be repeated 1 week and 3 months after the exam to measure thresholds (and other measurements)

Patient care

An advance cardiac life support (ACLS)-certified Cardiology physician, nurse practitioner or physician assistant, or alternatively, an ACLS-certified senior resident, fellow or attending physician of the primary care team will be present at the MR-console during the entire exam to monitor the patient and perform basic and advanced cardiac life support if needed
 Cardiologist will be present for on-line analysis of cardiac rhythm
 A pacemaker/ICD programmer will be present at the MR-scanner
 The patient will be monitored with ECG, and pulse oximetry during the entire exam. Optional: non-invasive blood pressure measurement and breathing sensors
 Audio and visual contact is preferred
 A crash cart with an external defibrillator-pacemaker (not AED) must be present at the MR scanner

^aData on >1.5 T systems is limited.

Thoughtful pre-MR reprogramming, careful monitoring during MR scan and thorough follow-up must be performed in any device patient considered for MR imaging. Finally, a physician knowledgeable in device therapy and programming should be present throughout the entire scanning event (Table 4) and full resuscitation facilities should be available on site.

Adherence to these practice guidelines may ensure that the implantable cardiac device patient can safely undergo MR imaging. Ultimately, a truly 'MR-safe' pacemaker and ICD system will need to be developed. Truly 'MR safe' pacemaker and ICD systems are under development and will hopefully enter first clinical phase II trials in the near future.

Recently, an international clinical study to confirm the safety and efficacy of the Medtronic EnRhythm[®] MRI SureScan[™] pacing system, the first-ever pacemaker system to be developed and tested specifically for safe use in MRI has started. Approximately, 350 individuals will participate in the study, and eligibility is based on the clinical indication for pacemaker implantation and a willingness and ability to undergo elective MRI scanning. The first specifically designed MR-compatible PM underwent successful MR imaging on April 10, 2007 (University Hospital Zurich, Switzerland).

The Reveal[®] Plus Insertable Loop Recorder (ILR) includes two surface electrodes to continuously monitor a patient's subcutaneous ECG. The device contains no lead wires or large loops of electrically conductive material. Reveal Plus can record an ECG at the time of a syncopal episode that may help rule in or rule out life-threatening arrhythmias. The new generation ILR will be marked by Medtronic as MR-safe.

Under these precautions (Table 4), the advantages of an MR examination in a patient with implanted pacemaker or ICD may outweigh the potential risks. Adherence to these practice guidelines may ensure that the implantable cardiac device patient can safely undergo MR imaging.

Summary

The diagnostic need for an MR study has to be evaluated individually, and if there is a true necessity, in the absence of an alternative imaging modality, MR imaging may be considered with the precautions and follow-up measures in accordance with our recommendation. Consequently, this position paper should not be interpreted as a recommendation for clinicians to perform routine MR imaging in pacemaker and/or ICD patients.

Similar to the recent FDA statement,⁵² we also view the published results as encouraging and believe that, on a case-by-case basis, the diagnostic benefit from MR imaging outweighs the presumed risks for some pacemaker and ICD patients. Thus, for some patients, the risks presented by MR imaging under specific, characterized scanning and monitoring conditions may be acceptable given the diagnostic benefit of this powerful imaging modality.

Conflict of interest: A.A. is a consultant for Boston Scientific, Medtronic and Sorin/Ela, and has received speaker fees from Boston Scientific, Medtronic, Sorin/Ela, Biotronik, and GE Healthcare. J.B. is a consultant for Biotronik, Boston Scientific, and St Jude. T.S. is a consultant to Medtronic.

Funding

Ariel Roguin is supported by the Morasha program of the Israel Science Foundation (Grant 1831/07), Mallat family award for biomedical research, the Samuel Mendel Chodowsky fund and the Chief Scientist Office of the Ministry of Health, Israel. Angelo Auricchio and the Fondazione Cardiocentro Ticino received fellowship grants from Medtronic, Boston Scientific and St. Jude. Josep Brugada has received research grants from Boston Scientific and Medtronic.

References

1. Pinski SL, Trohman RG. Interference in implanted cardiac devices: Part II. *Pacing Clin Electrophysiol* 2002;25:1496–509.
2. Niehaus M, Tebbenjohanns J. Electromagnetic interference in patients with implanted pacemakers or cardioverter-defibrillators. *Heart* 2001;86:246–8.
3. Marcu CB, Beek AM, van Rossum AC. Clinical applications of cardiovascular magnetic resonance imaging. *CMAJ* 2006;175:911–7.
4. Gerber BL, Garot J, Bluemke DA, Wu KC, Lima JA. Accuracy of contrast-enhanced magnetic resonance imaging in predicting improvement of regional myocardial function in patients after acute myocardial infarction. *Circulation* 2002;106:1083–9.
5. Kim RJ, Wu E, Rafael A, Chen EL, Parker MA, Simonetti O *et al.* The use of contrast-enhanced magnetic resonance imaging to identify reversible myocardial dysfunction. *N Engl J Med* 2000;343:1445–53.
6. Schwitler J, Nanz D, Kneifel S, Bertschinger K, Buchi M, Knusel PR *et al.* Assessment of myocardial perfusion in coronary artery disease by magnetic resonance: a comparison with positron emission tomography and coronary angiography. *Circulation* 2001;103:2230–5.
7. Kalin R, Stanton MS. Current clinical issues for MRI scanning of pacemaker and defibrillator patients. *Pacing Clin Electrophysiol* 2005;28:326–8.
8. Kanal E, Borgstede JP, Barkovich AJ *et al.* American College of Radiology—White Paper on MR safety: 2004 update and revisions. *AJR* 2004;182:1111–4.
9. Erlebacher JA, Cahill PT, Pannizzo F, Knowles JR. Effect of magnetic resonance imaging on DDD pacemakers. *Am J Cardiol* 1986;57:437–40.
10. Hayes DL, Vlietstra RE. Pacemaker malfunction. *Am Coll Physicians* 1993;119:828–35.
11. Pavlicek W, Geisinger M, Castle L, Borkowski GP, Meaney TF, Bream BL *et al.* The effects of NMR on patients with cardiac pacemakers. *Radiology* 1983;147:149–53.
12. Fetter J, Aram G, Holmes DR, Gray JE, Hayes DL. The effects of nuclear magnetic resonance imagers on external and implantable pulse generators. *Pacing Clin Electrophysiol* 1984;7:720–7.
13. Pohost GM, Blackwell GG, Shellock FG. Safety of patients with medical devices during application of magnetic resonance methods. *Ann NY Acad Sci* 1992;649:302–12.
14. Gimbel JR, Kanal E. Can patients with implantable pacemakers safely undergo magnetic resonance imaging? *J Am Coll Cardiol* 2004;43:1325–7.
15. Shellock FG, Crues JV III. MR safety and the American College of Radiology White Paper. *AJR* 2002;178:1349–52.
16. Irnich W, Irnich B, Bartsch C, Stertmann WA, Gufler H, Weiler G. Do we need pacemakers resistant to magnetic resonance imaging? *Europace* 2005;7:353–65.
17. Alagona P, Toole JC, Maniscalco BS, Glover MU, Abernathy GT, Prida XA. Nuclear magnetic resonance imaging in a patient with a DDD pacemaker. *Pacing Clin Electrophysiol* 1989;12:619–20.
18. Inbar S, Larson J, Burt T, Mafee M, Ezri MD. Case report: nuclear magnetic resonance imaging in a patient with a pacemaker. *Am J Med Sci* 1993;305:174–5.
19. Gimbel JR, Johnson D, Levine PA, Wilkoff BL. Safe performance of magnetic resonance imaging on five patients with permanent cardiac pacemakers. *Pacing Clin Electrophysiol* 1996;19:913–9.
20. Fontaine JM, Mohamed FB, Gottlieb C, Callans DJ, Marchlinski FE. Rapid ventricular pacing in a pacemaker patient undergoing magnetic resonance imaging. *Pacing Clin Electrophysiol* 1998;21:1336–9.
21. Garcia-Bolao I, Albaladejo V, Benito A, Alegria E, Zubieta JL. Magnetic resonance imaging in a patient with a dual-chamber pacemaker. *Acta Cardiologia* 1998;19:33–5.
22. Sommer T, Vahlhaus C, Lauck G, von Smekal A, Reinke M, Hofer U *et al.* MR imaging and cardiac pacemakers: in-vitro evaluation and in-vivo studies in 51 patients at 0.5 T. *Radiology* 2000;215:869–79.

23. Holmes DR, Hayes DL, Gray JE, Merideth J. The effects of magnetic resonance imaging on implantable pulse generators. *Pacing Clin Electrophysiol* 1986;9:360-70.
24. Lauck G, von Smekal A, Wolke S, Seelos KC, Jung W, Manz M *et al.* Effects of nuclear magnetic resonance imaging on cardiac pacemaker. *Pacing Clin Electrophysiol* 1995;18:1549-55.
25. Hayes DL, Holmes DR, Gray JE. Effect of 1.5 Tesla nuclear magnetic resonance imaging scanner on implanted permanent pacemakers. *J Am Coll Cardiol* 1987;10:782-6.
26. Achenbach S, Moshage W, Diem B, Bieberle T, Schibgilla V, Bachmann K. Effects of magnetic resonance imaging on cardiac pacemakers and electrodes. *Am Heart J* 1997;134:467-73.
27. Roguin A, Zviman MM, Meiningner GR, Rodrigues ER, Dickfeld TM, Bluemke DA *et al.* Modern pacemaker and implantable cardioverter/defibrillator systems can be magnetic resonance imaging safe: in vitro and in vivo assessment of safety and function at 1.5 T. *Circulation* 2004;110:475-82.
28. Schmiedel A, Hackenbroch M, Yang A, Nahle CP, Skowasch D, Meyer C *et al.* Magnetic resonance imaging of the brain in patients with cardiac pace makers. In-vitro- and in-vivo-evaluation at 1.5 Tesla. *Rofo* 2005;177:731-44.
29. Luechinger R, Zeijlemaker VA, Pedersen EM, Mortensen P, Falk E, Duru F *et al.* In vivo heating of pacemaker leads during magnetic resonance imaging. *Eur Heart J* 2005;26:376-83.
30. Luechinger R, Duru F, Scheidegger MB, Boesiger P, Candinas R. Force and torque effects of a 1.5-Tesla MRI scanner on cardiac pacemakers and ICDs. *Pacing Clin Electrophysiol* 2001;24:199-205.
31. Shinbane JS, Colletti PM, Shellock FG. MR in Patients with Pacemakers and ICDs: Defining the Issues. *J Cardiovasc Magn Reson* 2007;9:5-13.
32. Vahlhaus C, Sommer T, Lewalter T, Schimpf R, Schumacher B, Jung W *et al.* Interference with cardiac pacemakers by magnetic resonance imaging: are there irreversible changes at 0.5 Tesla? *Pacing Clin Electrophysiol* 2001;24:489-95.
33. Martin ET, Coman JA, Shellock FG, Pulling CC, Fair R, Jenkins K. Magnetic resonance imaging and cardiac pacemaker safety at 1.5-Tesla. *J Am Coll Cardiol* 2004;43:1315-24.
34. Sommer T, Naehle CP, Yang A, Zeijlemaker V, Hackenbroch M, Schmiedel A *et al.* Strategy for safe performance of extrathoracic magnetic resonance imaging at 1.5 Tesla in the presence of cardiac pacemakers in non-pacemaker-dependent patients: a prospective study with 115 examinations. *Circulation* 2006;114:1285-92.
35. Nazarian S, Roguin A, Zviman MM, Lardo AC, Dickfeld TL, Calkins H *et al.* Clinical utility and safety of a protocol for noncardiac and cardiac magnetic resonance imaging of patients with permanent pacemakers and implantable-cardioverter defibrillators at 1.5 Tesla. *Circulation* 2006;114:1277-84.
36. Goldsher D, Amikam S, Boulos M, Suleiman M, Shreiber R, Eran A *et al.* Magnetic resonance imaging for patients with permanent pacemakers: initial clinical experience. *Isr Med Assoc J* 2006;8:91-4.
37. Gimbel JR, Bailey SM, Tchou PJ, Ruggieri PM, Wilkoff BL. Strategies for the safe magnetic resonance imaging of pacemaker-dependent patients. *Pacing Clin Electrophysiol* 2005;28:1041-6.
38. Peden CJ, Collins AG, Butson PC, Whitwam JG, Young IR. Induction of microcurrents in critically ill patients in magnetic resonance systems. *Crit Care Med* 1993;21:1923-8.
39. Hartnell GG, Spence L, Hughes LA, Cohen MC, Saouaf R, Buff B. Safety of MR imaging in patients who have retained metallic materials after cardiac surgery. *AJR* 1997;168:1157-9.
40. Kanal E. Safety of MR imaging in patients with retained epicardial pacer wires (Letter). *AJR* 1998;170:213.
41. Naehle CP, Litt H, Lewalter T, Sommer T. Do we need pacemakers resistant to magnetic resonance imaging? *Europace* 2006;8:388.
42. Gimbel JR, Trohman RL, Lindsay WC, Wilckoff BL. Strategies for the safe performance of magnetic resonance imaging in selected ICD patients. *Pacing Clin Electrophysiol* 2002;25:618.
43. Anfinson OG, Berntsen RF, Aass H, Kongsgaard E, Amile JP. Implantable cardioverter defibrillator dysfunction during and after magnetic resonance imaging. *Pacing Clin Electrophysiol* 2002;25:1400-2.
44. Fiek M, Remp T, Reithmann C, Steinbeck G. Complete loss of ICD programmability after magnetic resonance imaging. *Pacing Clin Electrophysiol* 2000;27:1002-4.
45. Coman JA, Martin ET, Sandler DA, Pulling CC, Fair R, Jenkins K *et al.* Implantable cardiac defibrillator interactions with magnetic resonance imaging at 1.5 Tesla. *J Am Coll Cardiol* 2004;43:138A.
46. Naehle CP, Sommer T, Meyer C, Strach K, Kreuz J, Litt H *et al.* Strategy for safe performance of magnetic resonance imaging on a patient with implantable cardioverter defibrillator. *Pacing Clin Electrophysiol* 2006;29:113-6.
47. Wollmann C, Grude M, Tombach B, Kugel H, Heindel W, Breithardt G *et al.* Safe performance of magnetic resonance imaging on a patient with an ICD. *Pacing Clin Electrophysiol* 2005;28:339-42.
48. Roguin A, Donahue JK, Bomma CS, Bluemke DA, Halperin HR. Cardiac magnetic resonance imaging in a patient with implantable cardioverter-defibrillator. *Pacing Clin Electrophysiol* 2005;28:336-8.
49. Gimbel JR, Kanal E, Schwartz KM, Wilkoff BL. Outcome of magnetic resonance imaging (MRI) in selected patients with implantable cardioverter defibrillators (ICDs). *Pacing Clin Electrophysiol* 2005;28:270-3.
50. Loewy J, Loewy A, Kendall EJ. Reconsideration of Pacemakers and MR Imaging. *Radiographics* 2004;24:1257-67.
51. Schueler BA, Parrish TB, Lin J, Hammer BE, Pangrle BJ, Ritenour ER *et al.* MRI compatibility and visibility assessment of implantable medical devices. *J Magn Reson Imaging* 1999;9:596-603.
52. Faris OP, Shein M. Food and Drug Administration perspective: magnetic resonance imaging of pacemaker and implantable cardioverter-defibrillator patients. *Circulation* 2006;114:1232-3.