

Infusion Port Dislodgment of Bilateral Breast Tissue Expanders After MRI

H. Daniel Zegzula, MD

W. P. Andrew Lee, MD

Tissue expanders are placed routinely for breast reconstruction, and magnetic resonance imaging (MRI) is a common diagnostic procedure. Many studies have reported on the safety of MRI in patients with nonferromagnetic implants; however, many tissue expanders contain ferromagnetic components. The authors present a case of bilateral tissue expander infusion port dislodgment after MRI. A 56-year-old woman underwent bilateral mastectomy and immediate reconstruction with McGhan BIOSPAN tissue expanders. These implants contain integral nonferromagnetic infusion ports, as well as small, powerful Magna-Site magnets. Several weeks postoperatively the patient underwent MRI of her spine, which was ordered by her primary physician for back pain. Subsequently, the infusion ports could not be located with the finder magnet. A chest radiograph was obtained, which demonstrated bilateral dislodgment of the infusion ports. Surgical removal and replacement of the tissue expanders were required. Safety considerations of MRI have been discussed extensively in the literature, and data on MRI with various implanted devices have been obtained. The potential risks of performing MRI on patients with metallic implants include conduction of electrical currents, heating of the implant, misinterpretation resulting from artifact, and the possibility of movement or dislodgment of the implant. The small magnet integral to many tissue expanders may be overlooked by patients and physicians during pre-MRI screening. All patients undergoing tissue expansion with implants that contain integral ports should be thoroughly warned about the potential hazards of MRI.

Zegzula HD, Lee WP. Infusion port dislodgment of bilateral breast tissue expanders after mri. *Ann Plast Surg* 2001;46:46-48

From the Division of Plastic Surgery, Massachusetts General Hospital, Harvard Medical School, Boston, MA.

Received Jul 3, 2000. Accepted for publication Aug 3, 2000.

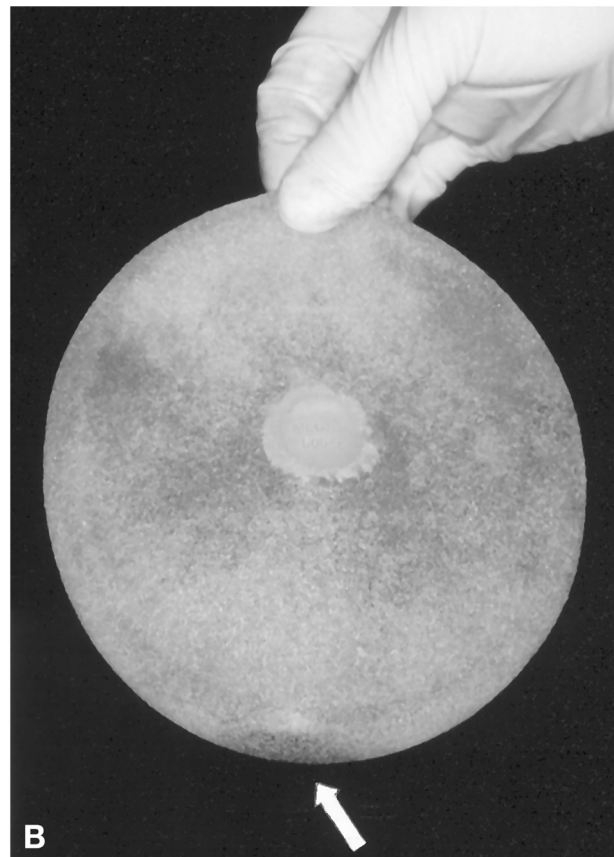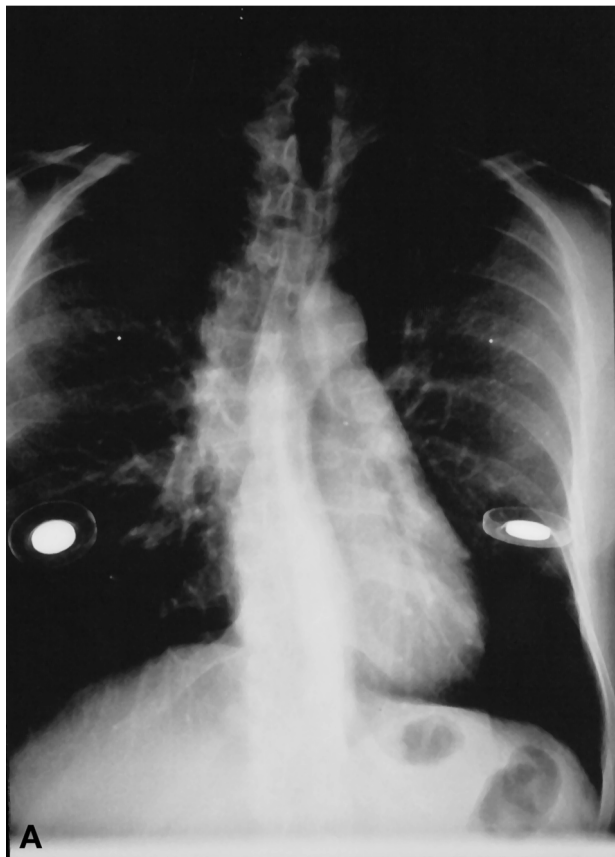
Address correspondence and reprint requests to Dr Lee, Wang Ambulatory Care Center, Suite 453, 15 Parkman Street, Boston, MA 02114.

Breast reconstruction using tissue expanders is a common reconstructive procedure. According to the 1998 Plastic Surgery Statistics of the American Society of Plastic Surgeons, there were nearly 70,000 surgical procedures performed in 1998 for breast reconstruction. Concurrently, magnetic resonance imaging (MRI) is increasingly popular because of its high accuracy and noninvasive nature. These patient populations can be ex-

pected to overlap with increasing frequency. The safety of performing MRI in the presence of nonferromagnetic biomedical implants is well established in the literature.^{1,2} However, certain breast tissue expanders contain small magnets to help localize the infusion ports integral to the device.³ These ferromagnetic components may be easily overlooked during pre-MRI screening. We present a patient with bilateral breast tissue expanders whose integral infusion ports were dislodged after MRI.

Patient Report

A 56-year-old woman with bilateral lobular breast carcinoma underwent bilateral modified radical mastectomy and immediate submuscular placement of tissue expanders. Two 600-ml McGhan (style 133 with Magna-Site integral port, Santa Barbara, CA) expanders were used. The procedure and postoperative recovery were uncomplicated. The patient elected to undergo chemotherapy, followed by radiation treatments, and this was started concurrently with serial expansion of her tissue expanders. Several weeks later, the patient developed new-onset back pain and was referred for MRI of her spine by her primary care physician. Subsequently the patient returned for additional expansion, but her infusion ports could not be located with the magnetic finder device. Implant migration was suspected, and radiographs were obtained that showed the infusion ports to be located at the most inferior aspect of the expander (FigA). The patient was brought to the operating room for implant revision. Examination of the implants revealed that the infusion ports were free floating within the intact silicone elastomer shells (FigB). It appeared that the ports had been pulled off or melted away from the internal lining of the implant. The patient's implants were replaced and she ultimately completed her reconstruction.



(A) Upright chest radiograph showing displacement of the expander infusion ports. (B) The infusion ports were found to be free floating within the intact elastomer shell. The arrow indicates the metallic port.

Discussion

The Magna-Site (McGhan Medical, Santa Barbara, CA) port became available with McGhan tissue expanders in 1987. It contains metallic components including a puncture-proof titanium needle guard and a small magnet made of Samarium cobalt. The port, along with its integral metallic components, is fused to the silicone expansion envelope of the expander. The port is designed to be used with the Magna-Finder locating device, which allows highly accurate localization of the port at the time of expander filling.

Safety data on MRI in the presence of hundreds of biomedical implants are available, and the consensus is that MRI in the presence of nonferromagnetic implants is safe.¹ Performing MRI in the presence of ferromagnetic implants is contraindicated, however. The potential risks to patients undergoing MRI with ferromagnetic implants include dislodgment or movement of the implant, and heating of the implant or conduction of electrical currents that may cause

injury or malfunction of the implant.^{2,4,5} Another potential risk includes misinterpretation of the MR image because of artifacts caused by the implant.⁶

These risks are not theoretical. Injuries have been reported in the literature, including deaths resulting from the movement of cerebrovascular aneurysm clips,⁷ and severe burns from pulse oximetry probes^{8,9} and permanent eyeliner.¹⁰ There are three reports in the literature of complications occurring in patients with breast tissue expanders with integral ports undergoing MRI: Complications included burning pain at the expander site during the procedure,¹¹ severe artifact that limited the value of an abdominal MRI,⁶ and dislodgment of one port in a patient with bilateral expanders while undergoing cervical spine MRI.¹²

Before an MRI procedure, every patient must undergo a pretest questionnaire and interview. Many patients with breast tissue expanders will refer to them as “breast implants,” and thus the

ferromagnetic components of their expanders may go undetected. The McGhan package insert for the Magna-Site expanders warns against MRI in patients with these expanders. Patients, however, may not read or understand that part of the insert. In each case reported earlier, the MRI was ordered by physicians other than the surgeon who placed the tissue expanders, indicating the ordering physician was not familiar with the technical aspects of the tissue expander. Patients, primary care physicians, radiologists, and anyone who may order an MRI exam needs to be fully informed of the potential risk in patients with integral port tissue expanders.

In summary, tissue expander breast reconstruction and MRI examinations are common procedures. These patient populations can be expected to overlap with increasing frequency. MRI is contraindicated in patients with ferromagnetic implants. Many patients and referring physicians do not understand that some tissue expanders contain small ferromagnetic components. We conclude that all patients undergoing tissue expander reconstruction with integral ports need to be thoroughly warned about the potential hazards of MRI.

References

- 1 Shellock FG, Morisoli S, Kanal E. MR procedures and biomedical implants, materials, and devices: 1993 update. *Radiology* 1993;189:587-599
- 2 Kanal E, Shellock FG, Talagala L. Safety considerations in MR imaging. *Radiology* 1990;176:593-606
- 3 Liang MD, Narayanan K, Kanal E. Magnetic ports in tissue expanders—a caution for MRI. *Magn Reson Imaging* 1989;7:541-542
- 4 Shellock FG, Crues JV. High-field-strength MR imaging and metallic biomedical implants: an ex vivo evaluation of deflection forces. *AJR Am J Roentgenol* 1988;151:389-392
- 5 Shuman WP, Haynor DR, Guy AW, et al. Superficial- and deep-tissue temperature increases in anesthetized dogs during exposure to high specific absorption rates in a 1.5-T MR imager. *Radiology* 1988;167:551-554
- 6 Feldman DR, Conway WF, Spicer KM. Ferromagnetic artifact from a tissue expander used for breast reconstruction. *Plast Reconstr Surg* 1995;95:426-427
- 7 Klucznik R, Carrier D, Pyka R, et al. Placement of a ferromagnetic interest cerebral aneurysm clip in a magnetic field with a fatal outcome. *Radiology* 1993;187:855-856
- 8 Kanal E, Shellock F. Burns associated with clinical MR examination. *Radiology* 1990;175:585 [Letter]
- 9 Shellock FG, Slimp GL. Severe burn of the finger caused by using a pulse oximeter during MR imaging. *AJR Am J Roentgenol* 1989;153:1105 [Letter]
- 10 Jackson J, Acker J. Permanent eyeliner in MR imaging. *AJR Am J Roentgenol* 1987;149:1080 [Letter]
- 11 Duffy Jr FJ, May Jr JW. Tissue expanders and magnetic resonance imaging: the “hot” breast implant. *Ann Plast Surg* 1995;35:647-649
- 12 Stueber K. A complication of tissue expander breast reconstruction. *Plast Reconstr Surg* 1997;99:1464-1465