

Intraocular Silicone Oil: In Vitro and In Vivo MR and CT Characteristics

Vincent P. Mathews, Allen D. Elster, Peter B. Barker, Bill L. Buff, Julia A. Haller, and Craig M. Greven

PURPOSE: To describe the CT and MR characteristics of intraocular silicone oil (polydimethylsiloxane), which is used with increasing frequency to treat complicated retinal detachments. **METHODS:** CT was performed on a silicone oil/water phantom and on a patient with retinal detachments secondary to cytomegalovirus retinitis, treated by bilateral intraocular injections of silicone oil. CT appearance and CT number of silicone oil were evaluated. Proton MR spectroscopy was performed with a 200-MHz spectrometer on a sample of polydimethylsiloxane within a tube of deuterated water. MR imaging was performed on a silicone oil/water phantom and on two patients with retinal detachments treated with silicone oil injection. **RESULTS:** Silicone oil is relatively radiodense; its CT attenuation is approximately 130 HU. On spectroscopy, silicone oil gave a single peak at 0.33 ppm. Relative to water silicone oil was hyperintense on T1-weighted images and hypointense on spin-density and T2-weighted images. Estimated T1 and T2 were 716 msec and 68 msec, respectively. Chemical shift artifacts were seen on MR images and were exaggerated when a narrow sampling bandwidth was used. In clinical cases spectral saturation pulses normally used for lipid suppression could be adjusted to saturate only the silicone resonance; in this way, the chemical shift artifact was eliminated. **CONCLUSION:** Intraocular silicone oil has unique imaging characteristics with which radiologists must become familiar. These characteristics include high attenuation on CT and hyperintensity on T1-weighted MR, both of which may mimic hemorrhage. Elimination of the prominent chemical shift artifact on MR with selective saturation of the silicone resonance improves evaluation of the globe.

Index terms: Silicone; Retina, computed tomography; Retina, magnetic resonance; Eyes

AJNR Am J Neuroradiol 15:343-347, Feb 1994

Liquid silicone has been used for vitreous replacement and internal tamponade of complex retinal detachments in humans since 1962 (1). Recently, intraocular silicone oil infusion has been used successfully to reattach the retina in patients with acquired immunodeficiency syndrome (AIDS) who have complex retinal detachments

related to cytomegalovirus infections (2-6). Because of high success rates, many ophthalmologists now use silicone oil tamponade as a primary retinal reattachment procedure in such patients (6). As the use of intraocular silicone oil increases in these patients, who frequently are studied by neuroradiology for other reasons, the importance of recognizing the appearance of silicone oil on neuroradiologic examinations also will increase.

The purpose of this study is to describe the computed tomography (CT) and magnetic resonance (MR) characteristics of the most frequently used intraocular silicone oil, polydimethylsiloxane. In vitro and in vivo characteristics reported include CT and MR appearances, CT attenuation value, proton nuclear MR chemical shift, and T1 and T2 relaxation times.

Materials and Methods

For all MR and CT studies we used the silicone oil polydimethylsiloxane (Escalon Ophthalmics, Skillman NJ,

Received November 5, 1992; accepted pending revision February 24, 1993; revision received March 12.

Presented at the Annual meeting of the American Society of Neuroradiology, Vancouver, British Columbia, May 1993.

From the Departments of Radiology (V.P.M., A.D.E., B.L.B.) and Ophthalmology (C.M.G.), Bowman Gray School of Medicine of Wake Forest University, Winston-Salem, NC; and the Departments of Radiology (P.B.B.) and Ophthalmology (J.A.H.), Johns Hopkins University School of Medicine, Baltimore, Md.

Address reprint requests to Vincent P. Mathews, MD, Department of Radiology, Bowman Gray School of Medicine, Medical Center Boulevard, Winston-Salem, NC 27157-1088.

AJNR 15:343-347, Feb 1994 0195-6108/94/1502-0343

© American Society of Neuroradiology

and Richard-James, Peabody, Mass), which has a viscosity of 5000 centistokes.

MR Phantom Study

Proton MR spectroscopy was performed with a VXR 200-MHz spectrometer (Varian Analytical Instruments, Sunnyvale, Calif). The probe temperature was 25°C. A polydimethylsiloxane sample was placed in the inner capillary of a concentric tube with deuterated water in the outer tube. The spectrum was obtained with the spectrometer locked on water as an internal reference.

A 10-mL vial of polydimethylsiloxane in a water bath was imaged at 1.5 T with a GE Signa (GE Medical Systems, Milwaukee, Wis) MR imaging unit. Double-echo spin-density-weighted (3000/31/1 [repetition time/echo time/excitations]) and T2-weighted (3000/90/1) images were obtained using a 32-kHz bandwidth on the first echo and a 10.68-kHz bandwidth on the second echo. A 20-cm field of view and 10-mm section thickness were used.

The T1 relaxation time was calculated by using scanner software after obtaining signal intensity measurements for the specimen with a constant echo time (40) and variable repetition time values (1000, 1500, and 2000). The T2 relaxation time was determined by performing a single multiecho study with constant repetition time (2000) and varying echo time (40 and 80).

CT Phantom Study

A syringe containing 10 mL of polydimethylsiloxane lying between two saline-filled bags was imaged with the following CT parameters: 10-mm section thickness, 10-cm field of view, 120 kV, and 70 mA. CT attenuation was measured by placing a region of interest on the image of the silicone oil and using the automated method of Hounsfield unit measurement available on the GE 9800 CT scanner.

Clinical Cases

Case 1. A 31-year-old human immunodeficiency virus-positive man developed intracranial toxoplasmosis, which was diagnosed on MR by the presence of multiple intraparenchymal lesions that responded to antitoxoplasma chemotherapy. He subsequently was diagnosed with cytomegalovirus retinitis and was treated with ganciclovir. A retinal detachment developed in his left eye and was treated by vitrectomy, retinal reattachment, and injection of silicone oil into the vitreous cavity for permanent retinal tamponade. Retinal reattachment was successful, and visual acuity returned to the 20/25 level. MR was performed to follow the response of the intracranial lesions to the antitoxoplasma therapy.

Case 2. A 69-year-old man was struck in the right eye with a nail and suffered a corneal laceration, dislocated lens, choroidal detachment, and a retinal tear. Initial treatment included vitrectomy, lens removal, and endophoto-

coagulation of the retinal tear. He presented again 3 weeks later with diminished vision and was found to have a total retinal detachment in the right eye, which was treated with further vitreoretinal surgery and silicone oil injection. An orbital MR study was obtained to evaluate the retina after surgery. T1-weighted images (700/23/1) were obtained first without and then with a saturation pulse positioned upfield from the lipid resonance.

Case 3. A 29-year-old man with AIDS who had bilateral cytomegalovirus retinitis developed retinal detachments first in his right eye and, 4 months later, in his left eye. On both occasions he was treated with vitrectomy, subretinal fluid drainage, photocoagulation, and intraocular silicone oil injections. Retinal reattachment was successful in both instances, but the patient experienced progressive decline in vision as a result of cytomegalovirus retinitis, which was unresponsive to ganciclovir and foscarnet. Two months after the procedure on his left eye, he was admitted with photophobia and meningismus. CT scans of the brain were obtained without and with iodinated contrast.

Results

MR Phantom Study

The proton spectrum is shown in Fig 1. With the water peak set to 4.67 ppm, the silicone polymer gave a single peak at 0.33 ppm. No other peaks were observed in the range of -4 to +8 ppm.

MR images of the phantom showed the silicone oil to be hypointense to water on both spin-density and T2-weighted images (Fig 2). The chemical shift in the frequency-encoding direction increased as the bandwidth was decreased on the second echo.

The estimated T1 and T2 values were 716 msec and 68 msec, respectively.

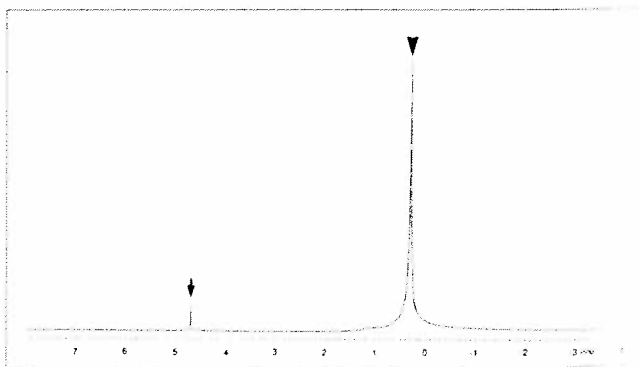


Fig. 1. Proton MR spectrum obtained from a 200-MHz high-resolution spectrometer shows a single peak at 0.33 ppm (arrowhead) from the protons of polydimethylsiloxane and a reference peak at 4.67 ppm (arrow) from the protons of D₂O/H₂O.

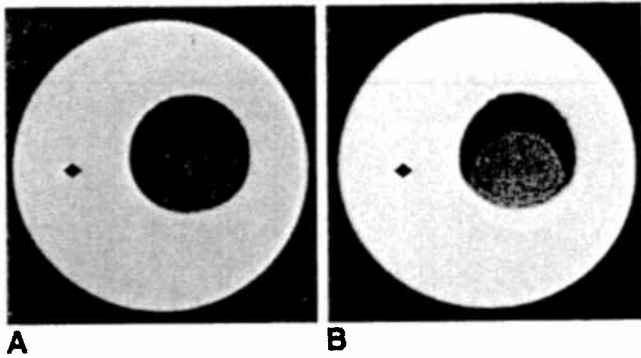


Fig. 2. MR images of a vial of silicone oil in a water bath.

A, Spin-density-weighted MR image (3000/31) obtained using a 32-kHz bandwidth shows (from outside to center) relatively hyperintense water (*diamond*), signal void from the glass vial, and relatively hypointense silicone oil (*asterisk*). The eccentric position of the silicone oil is caused by a chemical shift artifact in the frequency encoding direction.

B, T2-weighted MR image (3000/90) obtained with a 10.68-kHz bandwidth shows that the chemical shift artifact of silicone oil (*asterisk*) is exaggerated when a narrow bandwidth is used.

CT Phantom Study

The CT images demonstrated that the radiodensity of silicone oil (attenuation of 132 ± 2.8 HU) is greater than that of saline.

Clinical Cases

Case 1. The left globe, containing silicone oil, was hyperintense on T1-weighted images, isointense on spin-density-weighted images, and slightly hypointense on T2-weighted images in comparison with the vitreous in the untreated right globe. A chemical shift artifact was seen on all images but was largest on the second echo of the long TR images on which a narrow (± 4 kHz) bandwidth was used (Fig 3).

Case 2. MR imaging demonstrated that the right globe, which contained the silicone oil, was hyperintense in comparison with vitreous in the unaffected left globe on T1-weighted images. Additionally, after careful manual positioning of the saturation band slightly upfield from the normal lipid resonance, signal from the silicone oil could be selectively saturated without affecting the signal from retrobulbar fat or other orbital tissues (Fig 4). Selective saturation also eliminated the chemical shift artifact and permitted clear demarcation of the margins of the globe.

Case 3. Both globes were hyperdense on CT (Fig 5). The attenuation measured 113 ± 11 HU on the right and 130 ± 11 HU on the left.

Discussion

Siloxanes are compounds with Si—O bonds. Polydimethylsiloxane, which has the structure $(\text{—}(\text{CH}_3)_2\text{SiO—})_n$, is the compound used most often in reported studies of intraocular silicone oil. The viscosity of this oil is dependent on the chain length. High-viscosity (5000 centistokes) polydimethylsiloxane oil, which was used in our study, is currently favored because of its greater chemical stability (7).

Silicone oil used in ophthalmic applications is almost exclusively composed of long-chain molecules, whereas the silicone used in breast implants is a mixture of both short and long chains (Alan L. Weiner, PhD, personal communication, September 1992). Breast prostheses have been studied with MR, and the calculated T1 and T2 values (870 msec and 80 msec, respectively) (8) are similar to the values determined in our study. Liquid silicone testicular prostheses have also been studied with MR and proton MR spectroscopy and were noted to have a chemical shift of approximately -400 Hz relative to water (9) at 1.5 T, which translates to a peak resonating at -1.6 ppm, compared with our value of 0.33 ppm. The precise composition of the testicular prostheses was not identified in this report. It is not clear whether the difference in chemical shifts between silicone oil used for intraocular injection and silicone testicular prostheses is caused by significant differences in the structure of the compounds used, the presence of paramagnetic impurities in the testicular prostheses, or magnetic susceptibility effects. Because of the presence of the electronegative oxygen atoms in polydimethylsiloxane, a mild degree of deshielding of the protons of the methyl groups is expected. Consequently, a small downfield shift relative to the standard tetramethylsilane (0 ppm) is predictable. Our chemical shift measurement agrees with this theoretical prediction. The fact that the resonant frequency of polydimethylsiloxane does not overlap with the resonant frequency of lipid makes selective saturation of intraocular silicone oil possible. Selective saturation can be valuable in eliminating the chemical shift artifact, thereby improving image quality (Fig 4). The exaggerated chemical shift artifacts with narrow bandwidth images (Figs 2 and 3) can be explained by the inverse relationship between signal displacement and bandwidth (10).

The comparison of the MR signal intensities of ophthalmic silicone oil and the published signal intensities of silicone breast implants is compli-

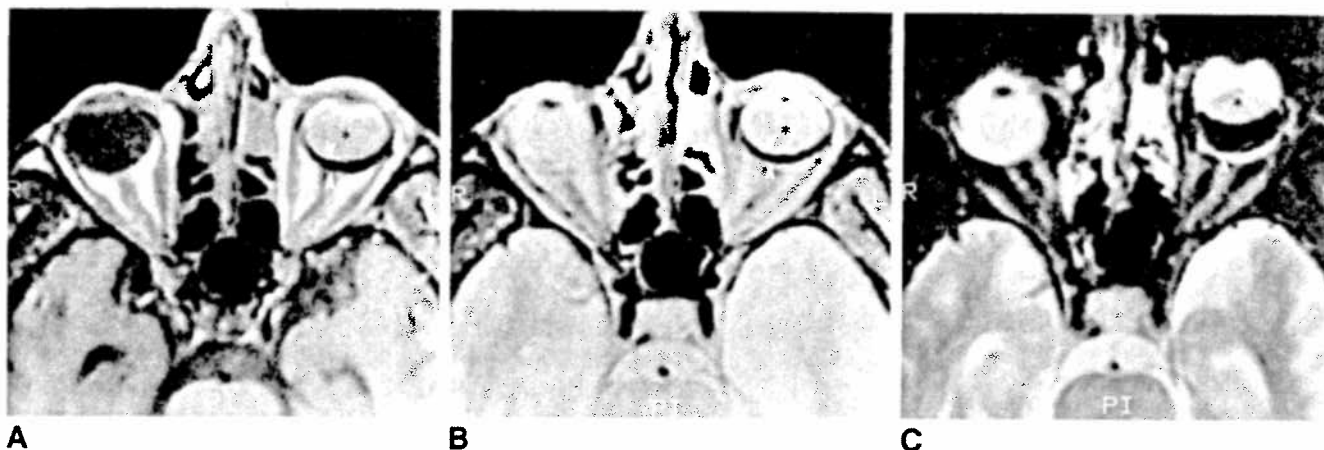


Fig. 3. MR study of a patient (case 1) with cytomegalovirus retinitis and a detached retina of the left eye treated with silicone oil injection. Compared with the normal vitreous in the right eye, silicone oil (*asterisk*) is hyperintense on T1-weighted images (A, 500/31), isointense on spin-density-weighted images (B, 3000/31), and hypointense on T2-weighted images (C, 3000/90). Note the chemical shift artifacts (*arrowheads*) on all images, particularly on the T2-weighted image, which was performed with a narrow bandwidth.

Fig. 4. MR study of a patient (case 2) with a traumatic complex retinal detachment treated with silicone oil injection.

A, T1-weighted image (700/23) shows that the right globe is filled with hyperintense material that demonstrates a chemical shift artifact.

B, T1-weighted image (700/23) with a saturation pulse positioned slightly (*upfield*) from the normal lipid resonance demonstrates no signal from the silicone oil-filled right globe but normal signal from surrounding structures.

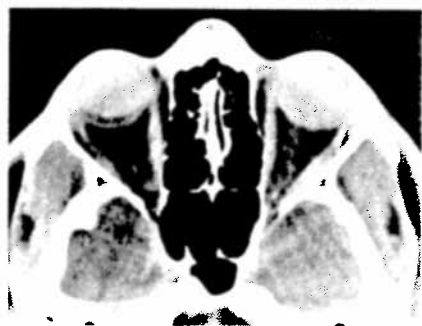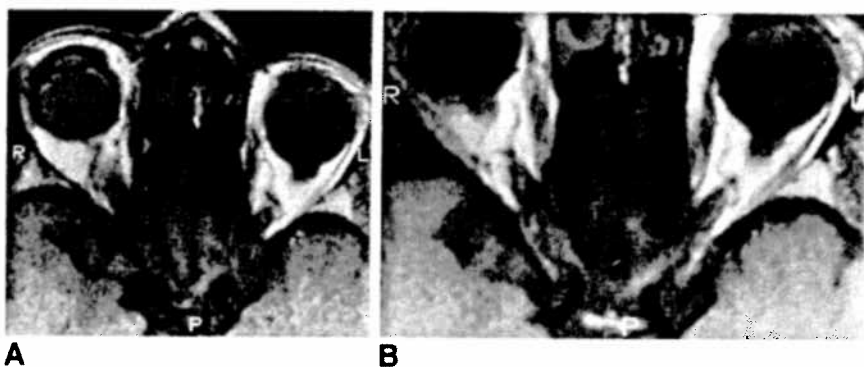


Fig. 5. CT scan of a patient (case 3) with bilateral retinal detachments secondary to cytomegalovirus retinitis treated with bilateral intraocular injections of silicone oil demonstrates abnormal increased attenuation of both globes (*right*, 113 HU; *left*, 130 HU).

cated by the different magnetic field strengths and pulse sequence parameters used in our study relative to previous studies (8, 11, 12). However, their similar T1 and T2 values and our clinical experience with imaging breast implants suggest that they have signal intensities similar to that of

intraocular silicone oil on T1-, T2-, and proton-density-weighted pulse sequences. Published MR images of silicone testicular prostheses (9) suggest that ophthalmic silicone oil and solid testicular prostheses have similar MR appearances. However, the liquid testicular prostheses have been reported to be of lower signal intensity than solid testicular prostheses (9) and, by inference, ophthalmic silicone oil. The reasons for this difference are unclear. In a previous report of intraocular silicone evaluated by MR, a less viscous silicone oil (1000 centistokes) was used, and a slightly higher signal was reported from the treated globe than from normal vitreous on all pulse sequences (13). These results contrast with our observations on clinical studies of hyperintensity on T1-weighted images, isointensity on spin-density-weighted images, and slight hypointensity on T2-weighted images. Different pulse sequence parameters in the two studies probably account for the discrepancy, because a more

heavily T2-weighted sequence was used in our study.

In a report of a ruptured silicone gel breast implant, CT demonstrated high-density globules representing free silicone (14), the density of which qualitatively resembles the density of intraocular silicone in our patient. Unless the radiologist is familiar with the appearance of silicone on CT scans, the high attenuation of this substance might be misinterpreted as hemorrhage. If surgical history is unavailable, direct measurement of attenuation will reveal significantly higher attenuation values for silicone oil (110 to 130 HU) than for blood (50 to 90 HU).

In conclusion, our study not only summarizes the MR and CT imaging features of silicone oil but also presents specific measurements of this substance, including nuclear MR frequency, T1 and T2 values, and CT number. The use of intraocular silicone oil will become more common in view of reports of its success in facilitating repair of complicated retinal detachments (15) and specifically in retinitis-related retinal detachments in patients with AIDS (2-6). It is important for radiologists to become familiar with the unique imaging characteristics of intraocular silicone, as its high attenuation on CT and hyperintensity on T1-weighted MR may be confused with intraocular hemorrhage. Awareness that silicone has a greater attenuation value than blood on CT and a chemical shift artifact on MR will help to prevent this confusion.

Acknowledgments

We thank Susan C. Jackels, PhD, and L. Henry Bryant, Jr, of Wake Forest University for performing the high-resolution MR spectroscopy and Alan L. Weiner, PhD, for providing us with valuable technical information concerning the Escalon product.

References

1. Cibis PA, Becker B, Okun E, Canaan S. The use of liquid silicone in retinal detachment surgery. *Arch Ophthalmol* 1962;68:590-599
2. Freeman WR, Henderly DE, Wan WL, et al. Prevalence, pathophysiology, and treatment of rhegmatogenous retinal detachment in treated cytomegalovirus retinitis. *Am J Ophthalmol* 1987;103:527-536
3. Jabs DA, Enger C, Haller J, de Bustros S. Retinal detachments in patients with cytomegalovirus retinitis. *Arch Ophthalmol* 1991;109:794-799
4. Sidikaro Y, Silver L, Holland GN, Kreiger AE. Rhegmatogenous retinal detachments in patients with AIDS and necrotizing retinal infections. *Ophthalmology* 1991;98:129-135
5. Orellano J, Teich SA, Lieberman RM, Restrepo S, Peairs R. Treatment of retinal detachments in patients with the acquired immune deficiency syndrome. *Ophthalmology* 1991;98:939-943
6. Regillo CD, Vander JF, Duker JS, Fischer DH, Belmont JB, Kleiner R. Repair of retinitis-related retinal detachments with silicone oil in patients with acquired immunodeficiency syndrome. *Am J Ophthalmol* 1992;113:21-27
7. Anonymous. Liquid silicone for complex retinal detachments (editorial). *Lancet* 1991;337:332-333
8. Heywang SH, Eiermann W, Bassermann R, Fenzl G. Carcinoma of the breast behind a prosthesis—comparison of ultrasound, mammography and MRI (case report). *Comput Radiol* 1985;9:283-286
9. Semelka R, Anderson M, Hricak H. Prosthetic testicle: appearance at MR imaging. *Radiology* 1989;173:561-562
10. Szumowski J, Simon JH. Proton chemical shift imaging. In: Stark DD, Bradley WG, eds. *Magnetic resonance imaging*. St Louis: Mosby-Year Book, 1992:485-488
11. Persellin ST, Vogler JB III, Brazis PW, Moy OJ. Detection of migratory silicone pseudotumor with use of magnetic resonance imaging. *Mayo Clin Proc* 1992;67:891-895
12. Heywang SH, Hilbertz T, Beck R, Bauer WM, Eiermann W, Permannetter W. Gd-DTPA-enhanced MR imaging of the breast in patients with postoperative scarring and silicon implants. *J Comput Assist Tomogr* 1990;14:348-356
13. Gross JG, Hesselink JR, Press GA, Goldbaum MH, Freeman WR. Magnetic resonance imaging in the evaluation of vitreoretinal disease in eyes with intraocular silicone oil. *Am J Ophthalmol* 1990;110:366-370
14. Scott IR, Müller NL, Fitzpatrick DG, Burhenne LJ. Ruptured breast implant: computed tomographic and mammographic findings. *Can Assoc Radiol J* 1988;39:152-154
15. Leaver PK, Grey RHB, Garner A. Silicone oil injection in treatment of massive preretinal retraction. II. Late complications in 93 eyes. *Br J Ophthalmol* 1979;63:361-367