

**Plastic & Reconstructive Surgery**

Issue: Volume 99(4) SUPPLEMENT 4, April 1997, pp 1464,1465

Copyright: (C)1997American Society of Plastic Surgeons

Publication Type: [Correspondence and Brief Communications]

ISSN: 0032-1052

Accession: 00006534-199704001-00050

[Correspondence and Brief Communications]

**A COMPLICATION OF TISSUE EXPANDER BREAST RECONSTRUCTION***Stueber, Kristen M.D.***▼ Author Information***Plastic and Reconstructive Surgery; Department of Surgery; Baystate Medical Center; Springfield, Mass. 01199*

I would like to bring to the attention of the readership an unusual sequel of a tissue expander breast reconstruction. Duffy and May <sup>1</sup> reported a complication of MRI in patients with tissue expanders with integral fill ports. We encountered another complication. This patient, with a strong family history of breast cancer, had elective bilateral mastectomies with placement of tissue expanders with integral valves. Several weeks postoperatively, she had an MRI study of her neck, ordered by another physician because of persistent neurologic symptoms. At the next visit for continued expansion, the fill valve could not be located with the magnet, and a chest x-ray showed the density of the valve to be located at the inferior aspect of the expander (Fig. 1). The patient then reported that she had the feeling of a brick falling on her chest during the examination. Because of concerns over the integrity of the expander, it was replaced. Upon removal, the shell of the expander was intact, but the metallic backing of the fill port was floating within the cavity of the expander (see Fig. 1).

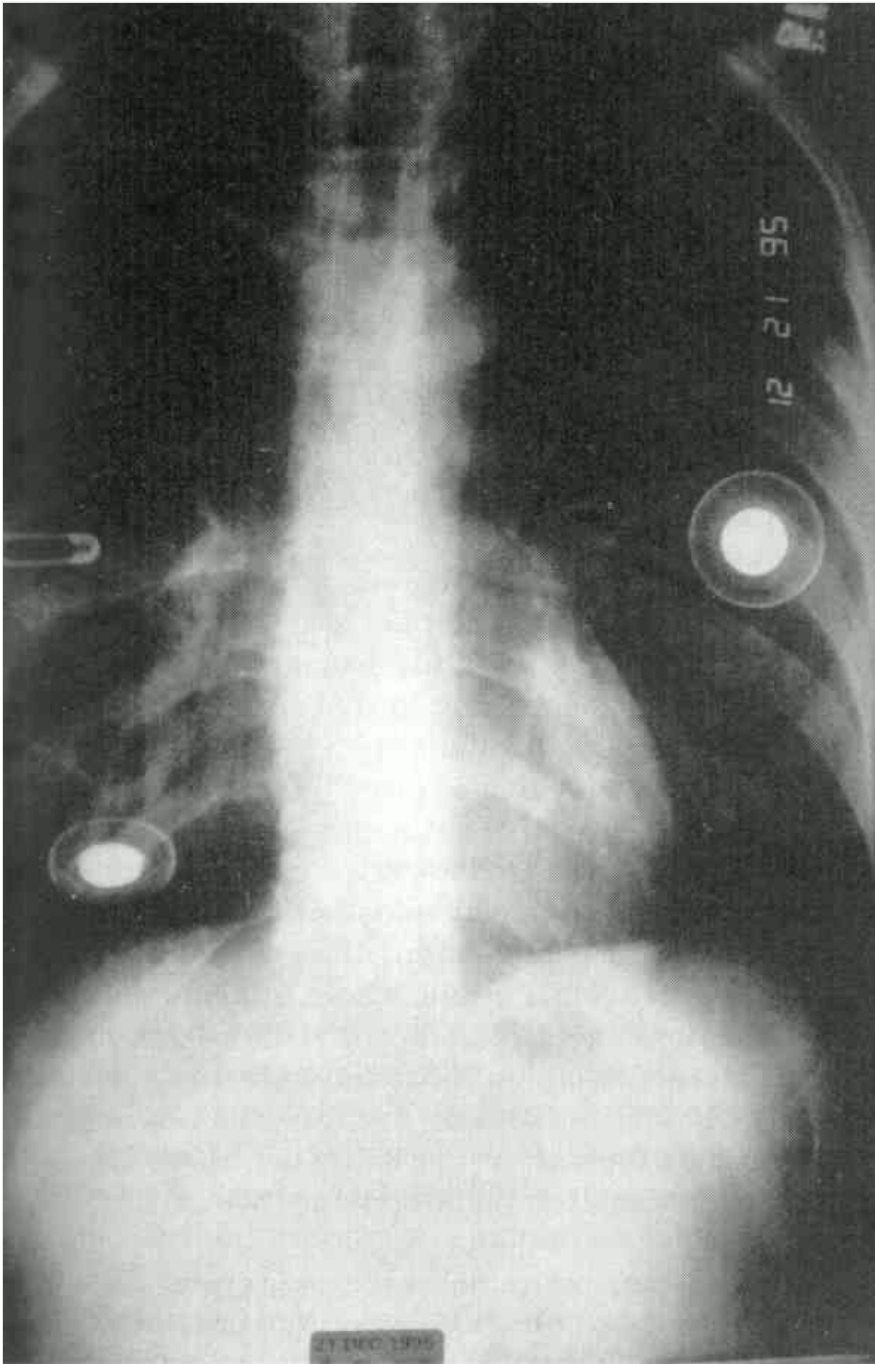


Fig. 1. Upright chest x-ray showing the disparity in the position of the fill ports.

Although the package insert warns against MRI studies in patients with tissue expanders, patients may not read or understand that part of the insert. Additionally, tests may be ordered by physicians not acquainted with the technical aspects of the tissue expander. Thus we advise physicians to caution every patient carefully that expanders with integral ports have magnetic material in them and should not be subjected to MRI scanning.

Kristen Stueber, M.D.

*Plastic and Reconstructive Surgery; Department of Surgery; Baystate Medical Center; Springfield, Mass. 01199*

## REFERENCE

1. Duffy, F. J., Jr., and May, J. W., Jr. Tissue expanders and magnetic resonance imaging: The "hot" breast implant. *Ann. Plast. Surg.* 35: 647, 1995. [Ovid Full Text](#) | [Bibliographic Links](#) | [Context Link](#)

## IMAGE GALLERY

Select All

 Export Selected to PowerPoint

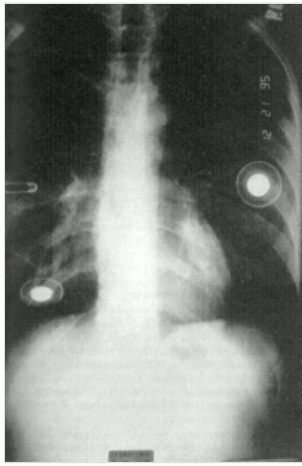


Fig. 1

[Back to Top](#)

[About Us](#) [Contact Us](#) [Privacy Policy](#) [Terms of Use](#)

© 2021 [Ovid Technologies, Inc.](#) All rights reserved. OvidUI\_04.12.00.019, SourceID 8a39b734572b4dbc6433090877fa2938a8775286