

Controversies in Cardiovascular MR Imaging: T2-weighted Imaging Should Not Be Used to Delineate the Area at Risk in Ischemic Myocardial Injury¹

Pierre Croisille, MD, PhD
Han W. Kim, MD
Raymond J. Kim, MD

The myocardial region that becomes ischemic after occlusion of its supplying coronary artery defines the area potentially at risk for infarction (hereafter, the area at risk). Without prompt restoration of blood flow, myocardial necrosis will ensue as a wavefront from the subendocardium to the subepicardium within the area at risk (1). Thus, in the setting of acute myocardial infarction (MI), the area at risk may include both infarcted (nonviable) and salvaged (viable) myocardium depending on the timeliness of reperfusion therapy.

Modern percutaneous revascularization techniques and pharmacologic therapies aim to salvage areas of acutely ischemic but reversibly injured myocardium, and these have proved to limit myocardial infarct size and reduce mortality (2). Although infarct size provides a rough (inverse) estimate of myocardial salvage, the extent of the area at risk is highly variable and dependent on coronary diameter, branching, and location of the occluding lesion (3). Thus, the proportion of the area at risk that was infarcted would be a better measure of therapeutic efficacy than would absolute infarct size. The rationale is that for two infarcts of the same size, the infarct that represents a larger proportion of the area at risk corresponds to a more severe degree of ischemic injury (Fig 1). Accordingly, it is critical to delineate the area at risk in patients, since it can yield essential clinical information concerning patient care and prognosis, and it is vital in clinical trials when used as a surrogate end point, since it provides an improved metric for the actual benefit of a given treatment.

Currently, there is considerable interest in cardiac applications for T2-weighted MR imaging in the scientific community, and since 2009, more than 600 articles pertaining to T2-weighted

MR imaging and the myocardial area at risk have been published (4). The prevailing thought is that the use of T2-weighted imaging to delineate the area at risk is ready for “prime time” (5). Undoubtedly, this application is being used to inform patient care decisions at some centers, and a search of two major clinical trial registries, www.clinicaltrials.gov (6) and Current Controlled Trials (7), showed that T2-weighted MR imaging was used to provide the primary or secondary end point in 20 trials that included more than 4000 patients worldwide. The assumption is that this technique is an established well-validated method with which to depict the area at risk. Unfortunately, there are several troubling aspects of the available evidence. Given the serious ramifications, we have critically reviewed the literature and examined the physiologic and technical assumptions underlying this application.

Inadequacy of Validation Studies

Three studies are widely quoted as proof that T2-weighted hyperintense regions delineate the myocardial area at risk after acute MI. Garcia-Dorado et al (8) demonstrated in 15 ex vivo pig hearts (nine reperfused, six nonreperfused) that the area of T2 hyperintensity was comparable to the area at risk defined at fluorescein staining. Unfortunately, the infarcted region was never delineated. Thus, the amount of salvage is unknown, and it is unclear whether there might have been an equally good correlation between T2 hyperintensity and infarct size. In addition, it is notable that the three largest areas at risk measurements, which primarily drive the correlation, were all from hearts with nonreperfused infarction, the group in which image intensity at T2-weighted MR imaging was only minimally elevated

Published online

10.1148/radiol.12111769 Content codes: **CA** **MR**

Radiology 2012; 265:12–22

¹From the Department of Radiology, Université Jean Monnet Saint-Etienne, CREATIS, UMR CNRS 5220-INSERM U1044, Lyon, France (P.C.); and Departments of Medicine (H.W.K., R.J.K.) and Radiology (R.J.K.), Duke Cardiovascular Magnetic Resonance Center, Duke University Medical Center, Box 3439, Durham, NC 27710. Received November 21, 2011; revision requested December 27; revision received January 23, 2012; accepted March 29; final version accepted April 23. Address correspondence to R.J.K. (e-mail: raymond.kim@duke.edu).

Potential conflicts of interest are listed at the end of this article.

See also the article by Arai et al in this issue.

© RSNA, 2012

Figure 1

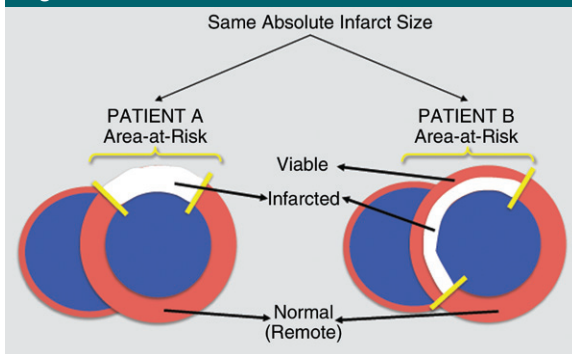


Figure 1: Diagram shows importance of determining area at risk. Two patients with the same absolute infarct size may have different amounts of salvage. In Patient A, the entire area at risk is transmurally infarcted, indicating prolonged ischemia, with no salvage. In Patient B, subendocardial infarction is present, suggesting shorter ischemia duration; however, since the area at risk is larger, there is substantial salvage.

in the ischemic zone and poorly correlated with myocardial water content.

Aletras et al (9) showed in nine canines with acute reperfused MI that the area of hyperintensity on T2-weighted images was similar to the area at risk measured with fluorescent microspheres and that both were larger than the infarct size defined at pathologic analysis. However, the map of the area at risk had poor spatial resolution because large separate tissue blocks were used for microsphere counting (16 full-thickness transmural sectors for each 8-mm short-axis section). Moreover, microspheres were injected during coronary occlusion on day 0, whereas T2-weighted MR imaging was performed on post-MI day 2. In the acute setting, infarct composition and volume are highly dynamic, and the changing reference base could affect the estimation of microsphere-determined blood flow within the ischemic zone (10) and the accuracy of area-at-risk size measurements.

Tilak et al (11) reported that in 14 canines with acute nonreperfused MI, the area of hyperintensity on T2-weighted images on post-MI day 2 correlated well with the area of hypoperfusion delineated by first-pass contrast material-enhanced MR imaging on day 0 and that both were larger than infarct size as measured with vital staining at pathologic analysis. Although fluorescent microspheres were administered in 12 animals, they were not used to measure the area at risk, and regrettably, a pathologic reference standard for the area at risk was not provided.

Thus, all three studies were small and had additional limitations. In particular,

many of the data and conclusions simply were based on size comparisons of abnormal regions defined by different MR imaging techniques or MR imaging and pathologic analysis. None of the studies showed any images or data allowing a direct comparison between the shape and contour of the T2-weighted abnormalities with the shape and contour of the area at risk, as delineated by microspheres, color dye, or any other appropriate pathologic reference standard. This is in contrast to the literature that validates the use of delayed-enhancement (DE) MR imaging in the identification of myocardial infarction, in which multiple studies show high-spatial-resolution examples detailing the precise match of the shape and contour of hyperenhancement by DE MR imaging with the shape and contour of infarction by pathology (12–14).

Numerous other studies have suggested that T2-weighted MR imaging can be used to identify the area at risk; however, these studies do not provide a comparison between MR images and a pathology reference for the area at risk. Rather, they infer that T2-weighted MR imaging depicts the area at risk since the T2 hyperintense region is larger than the infarct size, as determined with DE MR imaging or pathology (15–18). This type of evidence is indirect (19) and beset with several concerns that we will discuss later in this article.

A discussion of the evidence should include studies (if available) both for and against the use of T2-weighted MR imaging to delineate the area at risk.

Unfortunately, investigations that indicate T2-weighted MR imaging delineates the area of acute infarction rather than the area at risk have been given scant attention. Johnston et al (20) studied 19 canines that underwent 3-hour coronary occlusion with or without reperfusion. Despite a clear transmural reduction in blood flow in the ischemic zone as verified by radioactive microspheres (ie, the area at risk was fully transmural), T2 measured with nonlocalized MR spectroscopy was elevated only in the tissue samples from the endocardial half of the ischemic zone and not in the tissue samples from the epicardial half. Likewise, T2-weighted MR images demonstrated mostly subendocardial hyperintense regions. In a study of 16 canines with acute reperfused MI, Miller et al (21) reported that hyperintense regions on T2-weighted MR images were usually subendocardial and matched regions of infarction delineated at pathologic analysis rather than viable ischemic regions defined by radioactive microspheres. In nine control animals (seven of which received mannitol), T2 as measured with spectroscopy was elevated only in infarcted tissue and not in viable at-risk myocardium. In a separate study of 16 canines with variable coronary occlusion times, Ryan et al showed that only animals with infarction (verified with pathology) had hyperintense regions on T2-weighted MR images, whereas none of the animals without infarction had T2 abnormalities, despite regional systolic dysfunction (stunning) documented at the time of imaging (22). Moreover, T2 hyperintense regions correlated with infarct size but not with the area at risk, as delineated by contrast-enhanced echocardiography during coronary occlusion. Similar to the validation studies, these three investigations were small and had limitations. Nonetheless, these reports show that there are contributing data on both sides of the debate.

Physiologic Mechanisms of Elevated Myocardial T2

Edema in Irreversible versus Reversible Ischemic Injury

Signal intensity on T2-weighted MR images appears to be linearly related to

myocardial water content (8,23,24). However, from a mechanistic viewpoint, the underlying assumption that T2-weighted MR imaging depicts the area at risk because of edema is flawed. The experimental evidence points to substantial edema occurring in the infarcted region, with minimal or no edema occurring in the portion of the area at risk for a reversible injury. Specifically, Whalen et al (25) observed a 44% increase in water content (expressed as the difference of wet weight minus dry weight divided by dry weight) in myocardium exposed to ischemia sufficient to result in infarction of half of the tissue. From this, one can calculate that a pure sample of infarcted (irreversibly injured) myocardium would have an 88% increase in water content. In contrast, shorter periods of ischemia that result in solely reversible injury lead to only slight increases in water content. In a separate study, Jennings et al (26) reported a 9.6% increase in water content in myocardium reversibly injured by 15 minutes of ischemia followed by 20 minutes of reperfusion. However, up to 40% of the increase in tissue water may have been secondary to reactive hyperemia, which would be expected to resolve in a few hours (27). Moreover, since MR imaging is usually performed 1–7 days after an acute ischemic event, any small but measurable increase in tissue water seen at 20 minutes of reperfusion should be entirely resolved (28) at the time of MR imaging. Thus, reversible injury leads to minimal edema. The range in increased water content is 0%–10%, with the upper range expected to occur only for a brief period (<1 hour to 2 hours) after an ischemic event. Accordingly, the difference in edema between infarcted and salvaged (reversibly injured) myocardium should be large, and at a minimum, the ratio should be at least ninefold ($88\%/9.6\% = 9.2$).

This large difference in edema is likely why several investigators have found that regional end-diastolic wall thickness can double in the setting of reperfused transmural MI but that it is unchanged following shorter periods of ischemia with complete salvage (28–30).

Indeed, Haendchen et al (28) found that end-diastolic wall thickness early after ischemia and reperfusion correlates directly with the transmural extent of infarction, and they proposed that an acute increase in end-diastolic wall thickness might be used as an inverse index of salvage. Fully transmural infarcts were associated with a 100% increase in wall thickness, which is consistent with the 88% increase in water content calculated earlier (25,26).

Thus, if T2-weighted MR imaging enabled us to truly track edema, signal differences between infarcted and reversibly injured myocardium should be far greater than those between reversibly injured and normal myocardium. Assuming to first order that increases in image intensities on T2-weighted MR images are linearly related to increases in edema (8,23,24), one would expect for a 50% increase in signal within the infarct zone, a 0%–5% increase in signal for salvaged myocardium within the area at risk. Thus, even if salvaged myocardium could be distinguished from normal tissue, T2-weighted MR imaging should not show homogeneous hyperintensity throughout the area at risk, unless the area at risk was fully infarcted (ie, no salvage).

Unfortunately, many T2-weighted MR imaging articles (9,17,31) promulgate the idea that substantial edema occurs in reversibly injured myocardium by suggesting that this has been shown in prior physiology studies. However, the physiology studies cited do not distinguish edema associated with irreversible injury from edema associated with reversible injury (8,10,32,33). Since the studies involve severe ischemic injury in which substantial infarction is expected or shown, the data are equally consistent with much or all of the edema arising from only irreversible injury.

Bound Water?

Perhaps because of the conundrum concerning the lack of edema in salvaged myocardium, it has been proposed that changes in fractions of water (protein-bound water vs free water) rather than total water may explain the findings (5). This has led to a portrayal of ischemia as somehow “transforming water from its

‘bound’ (gel-like) form into a ‘free’ fluid state” (34). In regard to this hypothesis, we will discuss two issues.

The first is the theory that in protein solutions or in cells there are extensive regions of ordered or structured water surrounding macromolecules with drastically reduced motion characteristics (eg, rotational correlation times that are several orders of magnitude longer than those of bulk water). Although early publications theorized that frozen or gel-like hydration layers surrounded biopolymers (35–38), recent investigations have emphatically shown that there is little difference between water molecules in the protein surface hydration layer and those in bulk water (39). Both have approximately the same number of hydrogen bonds (40), and surface hydration water is highly mobile with subnanosecond residence times (41,42). Only a very few water molecules per protein, which are buried internally and are best regarded as an integral part of the protein, can be said to be bound in any sense (39). On the basis of these data, recent characterizations of ischemia (5,34) as somehow transforming water from gel-like to free or causing water release from cellular proteins appear fundamentally unsound.

Regardless of the exact nature of bound water, the second issue is whether a change in tissue T2 without a change in total water content is a reasonable mechanism to explain the observed T2-weighted MR findings. Certainly, it is well known that alterations in protein mobility and structure (such as by forming smaller or larger assemblies) without changes in overall protein mass or water volume can change T2 (43); however, the proposed mechanism is suspect for several reasons. First, there are no data that show protein mobility, protein structure, or both are grossly changed in salvaged myocardium. Second, if reversibly injured myocardium could have significantly elevated T2 without increased total water, this would be inconsistent with the totality of data showing a tight nearly linear relationship between T2 and total water in the initial MR studies (8,23,24). Third, if ischemia sufficient

Figure 2

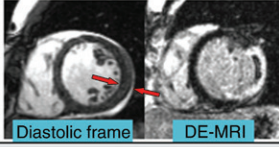
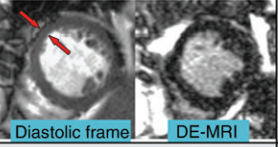




	Irreversible Injury (Infarcted)	Reversible Injury (Viable)	Normal (Remote)
Total Water Content (ref 25, 26)	↑~88%	↑ 0-10%	--
End Diastolic Wall Thickness (ref 28-30)	↑~100% 	minimal change 	--
Electrolytes (ref 25, 26, 45-47)	↑↑ changes	minimal change	--
Ultrastructure (ref 26, 44)	↑↑ changes 	minimal change 	-- 
²³ Na MRI (ref 47)			

Figure 2: Dramatic changes in patients with irreversible injury versus minimal changes in those with reversible injury. Expected changes in several biologic characteristics in myocardium after ischemic injury and reperfusion are summarized with comparison between irreversibly injured, reversibly injured, and normal tissue. Red arrows indicate regions that were akinetic at cine MR imaging (repetition time msec/echo time msec, 3.1/1.3; steady-state free precession sequence) from temporary occlusion to left circumflex and left anterior descending coronary arteries, respectively. Note the near doubling of end-diastolic wall thickness in the patient with transmural infarction, as shown by DE MR imaging (8.8/3.3, segmented inversion-recovery gradient-echo sequence). (Electron microscopy images reprinted, with permission, from references 26 and 44.) Irreversibly injured tissue shows greatly distorted ultrastructure at electron microscopy, with formation of vacuoles, large subsarcolemmal blebs, contraction bands, and swollen mitochondria containing dense bodies. In reversibly injured tissue, ultrastructure is virtually indistinguishable from healthy tissue in control subjects. Total myocardial sodium content as reflected by ²³Na MR imaging (8.1/3.9, gradient-echo sequence) is substantially elevated in infarcted regions but not in salvaged at-risk myocardium, which is consistent with changes in total water content measured in pathologic studies. (Reprinted, with permission, from reference 48.) Given these findings, it is perplexing that T2-weighted MR imaging apparently can be used to delineate between normal and reversibly injured tissue but cannot be used to differentiate between reversibly injured and infarcted tissue. TTC = triphenyltetrazolium chloride staining. (Adapted and reprinted, with permission, from reference 34.)

to result in reversible injury without edema can greatly elevate T2, why then does more severe ischemia that results in irreversible injury with substantial edema not result in even higher T2? It would seem that to account for homogeneous T2 hyperintensity throughout the area at risk in the setting of acute subendocardial infarction, a second unproven mechanism would need to be invoked to explain why larger amounts

of edema within infarcted tissue have no additional effect on T2. Fourth, T2 and T1 relaxation values of biologic tissues should reflect the composition and microenvironment of that tissue. However, after ischemia and reperfusion, the large differences in edema between myocardium with irreversible injury compared with myocardium with reversible injury are mirrored by similar large differences in electrolyte levels,

high-energy phosphate levels, and fine structure at light and electron microscopy (25,26,44-47). Sodium 23 (²³Na) MR imaging data are also consistent; large increases in sodium signal are only evident in infarcted myocardium (47). In brief, there are dramatic changes in all these characteristics in irreversibly injured tissue compared with minimal to no changes in reversibly injured tissue (Fig 2). Given the consistency of

these findings, it is perplexing that many investigators propose that T2-weighted MR imaging can be used to delineate between normal and reversibly injured tissue but not between reversibly injured and infarcted tissue.

Reperfusion Injury and Postconditioning: Effect on Retrospective T2-weighted MR Imaging

The area at risk is a coronary perfusion territory. Irrespective of the amount of edema within the area at risk, there is a fundamental limitation with defining the area at risk by using a nonperfusion-based indicator, such as edema, that can vary dramatically with different postreperfusion therapies. For instance, the process of restoring blood flow to ischemic myocardium can paradoxically reduce the beneficial effects of reperfusion and can account for up to 50% of final infarct size (49). In addition to myocyte necrosis, this so-called reperfusion injury may also result in microvascular obstruction and hemorrhage. Thus, from the time of reperfusion to the time when T2-weighted MR imaging is performed (often 1–7 days later), dynamic and complex changes to the tissue within the area at risk can occur. A perceived advantage of T2-weighted MR imaging is that it can be performed retrospectively after a patient with acute MI has received treatment and his or her condition has stabilized; however, regional T2 may be reduced, increased, or unchanged depending on specific tissue changes that occur after reperfusion.

An example of the complex tissue within the area at risk is myocardial hemorrhage, which is frequently found in the setting of reperfused acute MI. Lotan et al (50) have shown in a canine model that T2 was decreased in patients with hemorrhagic MI, increased in those with MI without hemorrhage, and similar to normal myocardium in regions with an admixture of hemorrhagic and nonhemorrhagic MI. Similarly, Mikami et al (51) found that signal intensity in microvascular obstruction regions on T2-weighted MR images was similar to that of remote myocardium and that 70% of the segments

with microvascular obstruction did not exhibit elevated signal intensity. The effect of hemorrhage on T2-weighted MR imaging measurements has been reported by O'Regan et al (52), who showed that when substantial hemorrhage is present, the size of the T2 abnormality could be significantly smaller than the infarct size.

Cardioprotection strategies focus on therapies given near the time of reperfusion and target postreperfusion cardiomyocyte death. Zhao et al (53) showed that after 60 minutes of sustained myocardial ischemia and 3 hours of reperfusion, postconditioning (ischemia-reperfusion cycles at the onset of reperfusion) could reduce infarct size in dogs from 25% to 14% and reduce water content in the area at risk. Proof-of-concept studies have shown that the effect of postconditioning can be extended to humans (54,55), and a growing number of clinical trials have been designed or are underway to investigate its different pathways (56). The Hatter Workshop recently made recommendations on the design of future cardioprotection trials and focused on the necessity to quantify the area at risk but raised a warning regarding T2-weighted MR imaging since “the concern with CMR [cardiac MR imaging] is whether the novel cardioprotective strategy itself may influence the extent of myocardial oedema by reducing it” (57). In summary, unlike the area at risk, which is simply a perfusion territory, image intensity at T2-weighted MR imaging is dependent on many factors, including the tissue changes that occur after reperfusion due to postreperfusion injury, postconditioning, and pharmacologic therapies that could have an antiedema effect.

Technical Issues: Different Size Does Not Always Equal Different Physiology

As noted earlier, numerous studies report bright regions on T2-weighted MR images are larger than those on DE MR images, and it is this literature that forms much of the evidence supporting the use of T2-weighted MR imaging to define the area at risk. However, there

are myriad reasons why T2-weighted MR imaging may result in overestimation of infarct size with DE MR imaging or pathologic analysis without the need to surmise that elevated signal intensity on T2-weighted MR images delineates the area at risk. These reasons will be discussed in the subsequent sections.

T2-weighted MR Imaging

Use of surface coils can lead to hyperintense regions simply based on proximity to the coil (Fig 3a). High signal intensity from static cavity blood may mimic myocardial edema, and motion-related signal loss in one region may cause other regions to appear hyperintense despite no actual changes in T2 signal (Fig 3b–3d). The latter two artifacts are particularly pernicious, in that these may be associated with physiologic changes occurring after MI rather than occurring randomly. Specifically, injured myocardium is often hypokinetic, which in turn can be associated with adjacent stagnant cavity blood. Likewise, hypokinetic myocardium, even without edema, may appear hyperintense in comparison with normal regions that have experienced signal loss because of vigorous motion. Newer bright-blood techniques with or without T2 mapping may substantially reduce these artifacts (58–60); however, there are no data validating these newer techniques in comparison with a true pathologic reference standard of the area at risk. Moreover, T2 mapping is not a panacea (Fig 4). It has limited spatial resolution and the chance for misregistration between frames with different T2 preparation times, both of which will lead to worse partial volume effects. A motion-compensation algorithm may limit in-plane misregistration, but acquisition of two-dimensional images will not allow compensation for through-plane motion. Finally, all T2 techniques, including T2 mapping, are limited by the relatively small changes in T2 expected for edematous myocardium. Aletras et al (9) reported a contrast-to-noise ratio between hyperintense and normal regions of only 2.9 for T2-weighted MR imaging; this is substantially less than the typical contrast-to-noise ratio of 19 for DE MR imaging (61).

Figure 3

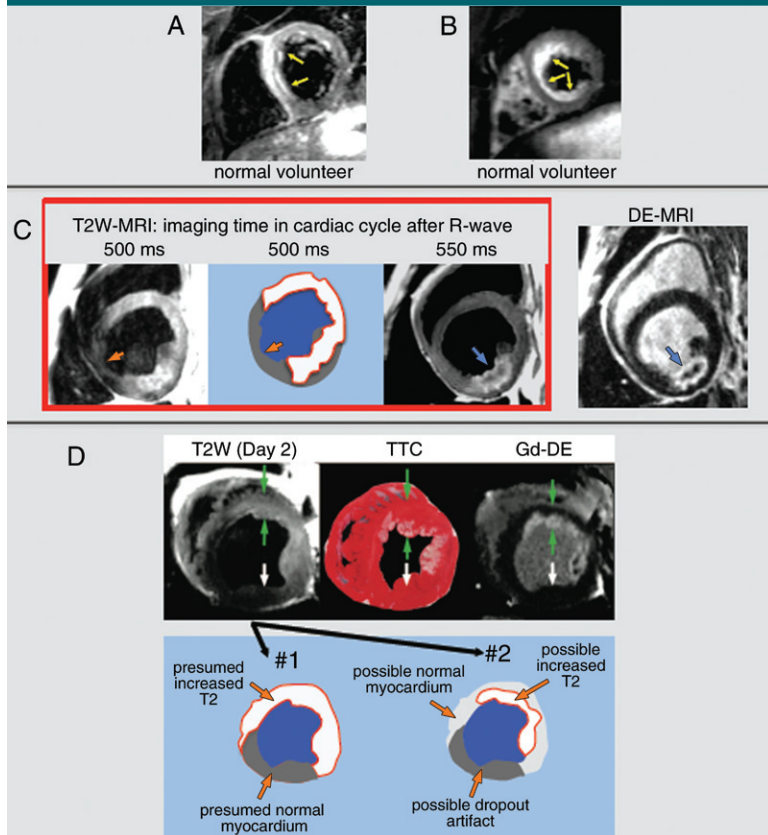


Figure 3: T2-weighted MR images and schematic drawings show technical limitations in the form of artifacts mimicking edema and leading to overestimation of T2 size. *A, B*, Conventional T2-weighted MR images (double-inversion fast spin-echo sequence, two R-R intervals/80) show hyperintense regions may occur in healthy volunteers because of, *A*, inhomogeneities in myocardial signal intensity and, *B*, slow cavity blood flow. *C*, T2-weighted images show that simply changing the timing of T2-weighted imaging during the cardiac cycle can lead to different regions of hyperintensity. If a region of signal intensity loss (orange arrows) is considered an area of normal myocardium, extent of hyperintensity may be large (red contour). In the image obtained 550 msec after the R wave, hyperintense region (blue arrow) is not fully transmural, and shape and contour appear to exactly match those of the infarcted region seen at DE MR imaging (*DE-MR*). (Adapted and reprinted, with permission, from reference 34.) *D*, Top: Green arrows = area of transmural edema and subendocardial infarction. White arrows = normal myocardium. (Reprinted, with permission, from reference 11.) Bottom: Drawings show our renditions of potential myocardial borders based on the T2-weighted MR image. If the area with the lowest signal intensity is considered normal (#1), the hyperintense region (white with red contour) is large. If the area with lowest signal intensity is considered artifactual and an intermediate-intensity region is considered normal (#2), there appears to be a smaller region of hyperintensity (white with red contour) that is similar in shape to the area of infarction.

Comparisons with DE MR Imaging

There can also be image quality issues with DE MR imaging (segmented, inversion-recovery gradient-echo, or steady-state free precession sequences [62]). A common problem encountered in our MR imaging core laboratory is the incorrect setting of inversion time. Often, a range of inversion times will lead to relative nulling of normal myocardium; however, it is important to use the longest time possible that still nulls normal myocardium (62). An inversion time that is too short might result in nulling of the periphery of a dense infarct (hyperenhancement size will be smaller than actual infarct size), or in the case of a patchy infarct, the entire area may be nulled, rendering it undetectable (Fig 5a). Since the concentration of gadolinium in blood decreases over time, the inversion time needs to be adjusted upward during the examination unless phase-sensitive sequences

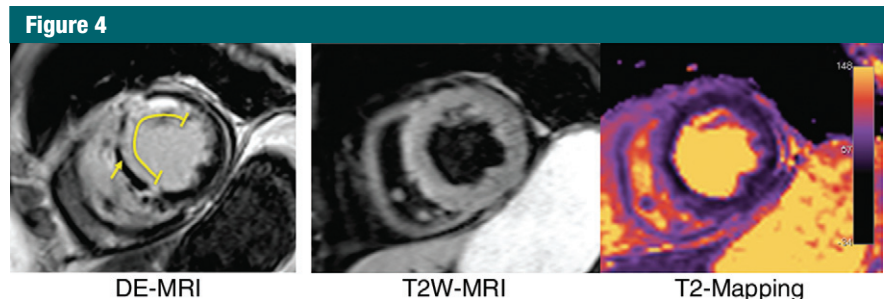


Figure 4: Left: DE MR image (segmented inversion-recovery gradient-echo sequence, 8.8/3.3) shows transmural anteroseptal myocardial infarction (yellow line) with microvascular obstruction (no reflow) (yellow arrow). Middle and right: Conventional dark-blood T2-weighted (double inversion-recovery fast spin-echo sequence, two R-R intervals/70) (middle) and T2 mapping (steady-state free precession sequence, 2.8/1.2) (right) MR images show an obvious region of T2 hyperintensity or elevated T2, respectively, is not evident, perhaps due to tissue changes associated with the no-reflow zone.

are used (63). Even if imaging is perfectly performed, the T1 of infarcted tissue and left ventricular cavity blood may be similar, and it may be difficult to identify the infarct endocardial border (62). This can lead to underestimation

of infarct size and transmuralty (Fig 5b).

Another important issue is the method of image analysis; that is, the way in which hyperintense regions are defined and sizes are quantified. Many

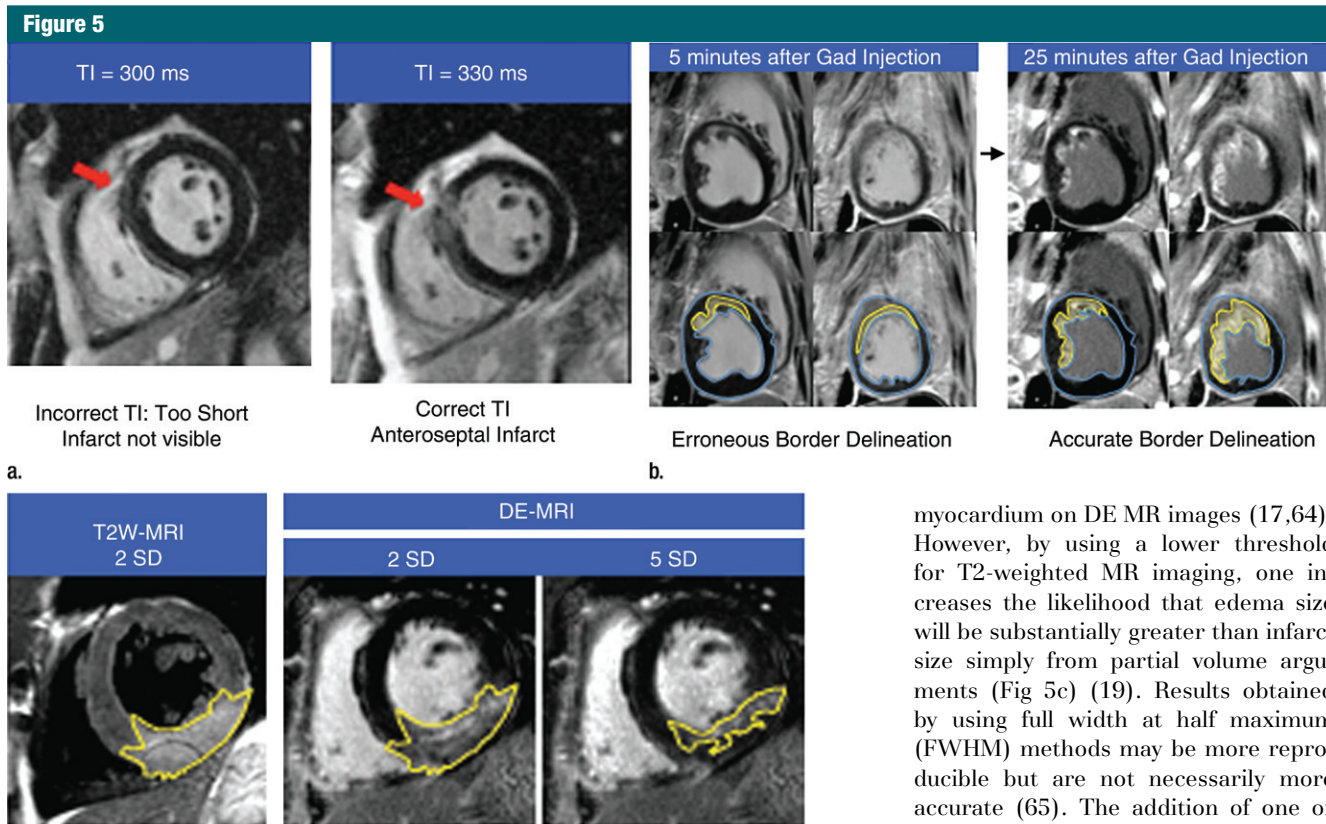


Figure 5: (a–c) Technical limitations of DE MR imaging are related to common issues leading to underestimation of infarct size. (a) Incorrect selection of inversion time (TI) may lead to underestimation of infarct size (segmented inversion-recovery gradient-echo sequence, 8.8/3.3). Without careful inspection, both images appear to have appropriately nulled (black) myocardium. Left: Normal myocardium has a faint etched appearance (darkest at endocardial and epicardial borders, with slightly higher image intensity centrally), signifying an inversion time that was set too short. Right: Imaging was repeated with inversion time set 30 msec longer and revealed a patchy anteroseptal infarct (arrows) that was not seen when the inversion time was set too short. (b) Poor image contrast between LV blood pool and infarcted myocardium may lead to underestimation of infarct size. Left: DE MR images obtained 5 minutes after gadolinium chelate (*Gad*) injection are shown with (top) and without (bottom) apparent myocardial and infarct contours. Blood pool and infarcted myocardium have similar image intensities, making segmentation difficult. Right: DE MR images in the same subject obtained 25 minutes after contrast material administration are shown with (top) and without (bottom) apparent myocardial and infarct contours. Border delineation is improved due to clearance of contrast material from the blood, and both transmural and circumferential extents of infarction are larger on the right. (c) Choice of an arbitrary threshold to define abnormal myocardium at T2-weighted MR imaging versus DE MR imaging may create artificial discrepancies in size. An inferior area of edema at T2-weighted MR imaging (double inversion-recovery fast spin-echo sequence, two R-R intervals/80 msec) appears to match area of infarction when both T2-weighted MR and DE MR images are windowed to highlight myocardium more than two standard deviations (SD) above remote signal intensity. In this situation, amount of salvage would be zero. However, area of edema is far larger than area of infarction when the same DE MR imaging data are windowed to highlight myocardium more than five standard deviations above remote signal intensity (substantial salvage is now present). (Adapted and reprinted, with permission, from reference 19.)

studies have arbitrarily defined bright myocardium as a region with signal intensity more than 2 standard deviations

above remote myocardium on T2-weighted MR images but more than five standard deviations above remote

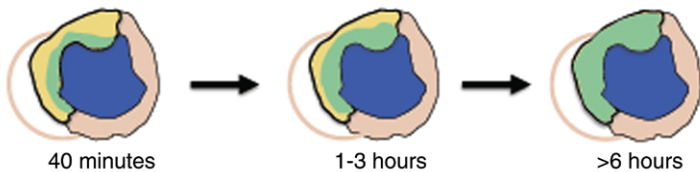
myocardium on DE MR images (17,64). However, by using a lower threshold for T2-weighted MR imaging, one increases the likelihood that edema size will be substantially greater than infarct size simply from partial volume arguments (Fig 5c) (19). Results obtained by using full width at half maximum (FWHM) methods may be more reproducible but are not necessarily more accurate (65). The addition of one or two very bright pixels within the hyper-enhancement zone may substantially reduce measured infarct size by raising the FWHM threshold and rendering a majority of the gray zone (admixture of infarcted and viable myocardium) part of the normal tissue. Moreover, given the large difference in contrast-to-noise ratio between T2-weighted MR imaging and DE MR imaging, the thresholds provided by the FWHM method may still be unbalanced. Specifically, it is known that FWHM yields infarct sizes similar to those obtained by using a 5- or 6-standard deviation threshold at DE MR imaging (66). It is improbable that FWHM yields edema sizes similar to those obtained by using a five- or six-standard-deviation threshold at T2-weighted MR imaging, given its low contrast-to-noise ratio.

Our goal in this section is not to provide an exhaustive list of potential problems but to point out that the technical issues are not the same for different MR imaging techniques. Most of the problems with T2-weighted MR imaging lead to overestimation of abnormal regions,

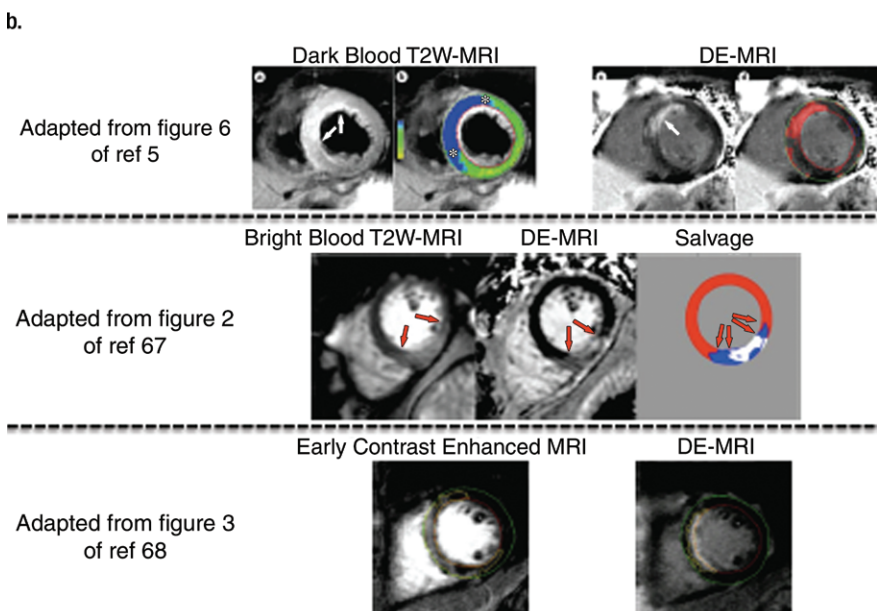
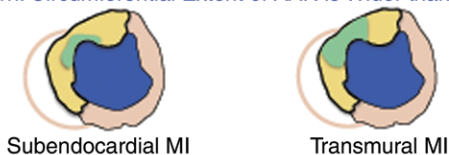
Figure 6

■ Infarcted ■ Viable (Salvaged) ■ Normal Myocardium ■+■=Area-at-Risk

Wavefront Phenomenon



a.
"Bull's-eye" Pattern: Circumferential Extent of AAR is Wider than that of Infarction



c.

whereas many of the problems with DE MR imaging lead to underestimation. Given these issues, we believe it is perilous to impute physiologic meaning solely on the basis of size differences between the two sets of MR images.

T2-weighted MR imaging is an artifact or if it is real? Some clues are found by returning to bedrock physiologic principles. After coronary occlusion, cell death is not simultaneous throughout the area at risk but progresses as a wavefront from the endocardium to the epicardium over several hours (Fig 6a) (1). Without timely reperfusion, infarction becomes transmural, reflecting an absence of salvageable myocardium within the area at risk. Thus, if the size of the area at risk measured with T2-weighted MR imaging is larger than

Figure 6: (a) Reimer and Jennings (1) state the following: "Necrosis occurs first in the subendocardial myocardium. With longer occlusions, a wavefront of cell death moves from the subendocardial zone across the wall to involve progressively more transmural thickness of the ischemic zone. Thus, there is typically a large zone of subepicardial myocardium in the ischemic bed that is salvageable by early reperfusion but that dies in the absence of such an intervention. In contrast, the lateral margins in the subendocardial region of the infarct are established as early as 40 minutes after occlusion and are sharply defined by the anatomic boundaries of the ischemic bed." (Adapted and reprinted, with permission, from reference 1.) (b) After subendocardial infarction has been established, lateral margins of infarct should be defined by area at risk. Accordingly, salvage can only occur in subepicardium of ischemic bed, and there cannot be any meaningful salvage at lateral borders of the infarct. A bull's-eye pattern of ischemia (where lateral borders of area at risk extend far beyond those of the infarct) is incompatible with the wavefront phenomenon and has no physiologic basis. (c) Albeit without physiologic basis, examples where the lateral borders of the area at risk extend well beyond those of the infarct are common in the literature, and some are shown here. Top: Conventional, dark-blood T2-weighted MR images show T2 hyperintense region is bright on gray-scale image and blue on color-coded image. Borders of T2 hyperintense regions (arrows on gray-scale image, * on color-coded image) extend well beyond lateral borders of near-transmural infarct on DE MR image (arrow on gray-scale image, red zone on color-coded image). (Reprinted, with permission, from reference 5). Middle: Bright-blood T2-weighted MR images show borders of T2 hyperintense region (arrows on bright-blood T2-weighted MR images, blue area on drawing) extend well beyond lateral border of near-transmural infarct (arrows on DE MR image, white area on drawing). (Reprinted, with permission, from reference 67.) Bottom: Early gadolinium enhancement. Borders delineated by early (2 minutes after gadolinium chelate administration) contrast-enhanced MR imaging extend well beyond lateral border of subendocardial MI and appear to encompass both the left anterior descending and right coronary artery perfusion territories. (Reprinted, with permission, from reference 68.)

Physiologic and Nonphysiologic Relationships between the Area at Risk and Infarction: The Wavefront Phenomenon Revisited

How can we know whether the consistent overestimation of infarct size at

the infarct size in the setting of transmural infarction, this is nonphysiologic (Fig 6b). Thus, it is puzzling that Berry et al (69) used bright-blood T2 techniques and reported similar amounts of

salvage, which was substantial, for both transmural infarction and nontransmural infarction. We are unaware of any other studies in which the authors report the amount of salvage as determined with T2-weighted MR imaging as a function of infarct transmurality.

In their landmark study of the wavefront phenomenon, Reimer and Jennings (1) describe a corollary principle—that is, that there is no wavefront circumferentially since there is no perfusion gradient in that direction. Reperfusion after only 40 minutes of ischemia resulted in a confluent subendocardial infarct (approximately 28% transmural), which already extended to within 1–2 mm of the lateral edge of the area at risk. Although some investigators initially suggested the existence of a wide lateral border zone of intermediate-level perfusion, later studies showed this was a partial volume artifact due to the limited resolution of the techniques used, and indeed, with progressively higher levels of sampling resolution, investigators have concluded that there is no zone of intermediate perfusion (or injury) at the lateral border (70,71). Although intramural and epicardial collateral anastomoses have been described in various species, detailed anatomic studies have shown end capillary loops without microvascular connections between adjacent vascular beds both in dogs and in humans (72,73). These data indicate there is no anatomic basis for a lateral border zone and render as incorrect a relationship between the area at risk and infarction based on a bull's-eye pattern of centrally severe ischemia, with gradients of increasing collateral flow in transmural and circumferential directions toward the edges of the ischemic region (Fig 6b).

The implication of the underlying physiology is that there cannot be any meaningful salvage at the lateral borders of the infarct. One potential caveat should be mentioned. In patients with multivessel disease, it is possible that the infarct-related artery prior to occlusion provided substantial collateral flow to a second coronary artery perfusion

territory. Thus, during infarction, a second vascular bed becomes ischemic. Theoretically, this could result in an area at risk that extends laterally beyond the infarct. However, in this special situation: (a) the entire circumference of the second vascular bed should be equally ischemic (the lateral border should not be just a bit bigger); (b) the level of ischemia needs to be within a narrow range that does not result in subendocardial infarction within the second bed (otherwise, again, there would be no salvage at the lateral borders of infarction); (c) this is known to be very rare, even in the setting of chronic diffuse multivessel disease (3); and (d) the area at risk should extend laterally only on one side of the infarct, since it is improbable that a rare event would occur twice at the same time.

However, the literature is replete with examples of T2 hyperintensity extending laterally, usually in both directions, far beyond the lateral border of the infarct delineated by DE MR imaging (Fig 6c). This finding is not limited to studies in which conventional black-blood T2-weighted MR imaging is used; it extends to newer bright-blood T2 techniques (67) and even contrast-enhanced MR imaging if performed very soon after gadolinium chelate administration (68). Unfortunately, in these studies, the discordance between MR imaging data and the underlying physiology is ignored.

Nonetheless, what can we make of the ubiquitous finding that abnormal regions defined by T2-weighted MR imaging appear larger than regions of infarction? Perhaps a look to the past may be instructive. It is clear that DE MR imaging is the reference standard in the delineation of myocardial infarction (65). However, before the remarkable improvement in image quality yielded by current inversion-recovery techniques (12,61), many believed that hyperenhanced regions in the setting of acute MI included viable myocardium, since numerous studies reported hyperenhancement size appeared larger than that of infarction (74,75). The history of DE MR imaging yields two lessons: First, when image quality is modest,

speculations concerning the underlying physiology are hazardous. Second, a definitive validation study should take precedence over reports, no matter how numerous, in which the evidence is simply size differences measured on MR imaging data sets.

Summary

The use of T2-weighted MR imaging to delineate the area at risk and subsequently quantify myocardial salvage is problematic on many levels. The validation studies available thus far are inadequate. Unlike the data validating DE MR imaging, in which pathologic analysis has shown the precise shape and contour of the bright region exactly match the infarcted area, this level of validation does not exist for T2-weighted MR imaging. Technical advances have occurred, but image contrast between abnormal and normal regions remains limited, and in this situation, measured size differences between MR imaging data sets should not be overinterpreted. Moreover, with any T2 technique, there remains the key issue that there is no physiologic basis for the apparent T2 findings. Indeed, a homogeneously bright area at risk on T2-weighted MR images is incompatible with the known levels of edema that occur in infarcted and salvaged myocardium, and the finding that the lateral borders of T2 hyperintense regions frequently extend far beyond that of infarction is contrary to the wavefront phenomenon. Even if T2-weighted MR imaging provided an accurate measure of myocardial edema, the level of edema within the area at risk is dependent on multiple variables, including infarct size, age, reperfusion status, reperfusion injury, and therapies that could have an antiedema effect. The area at risk is a coronary perfusion territory. There is a fundamental limitation with defining the area at risk by using a nonperfusion-based indicator that can vary with different postreperfusion therapies. There are several applications for T2 myocardial imaging, including differentiation of acute

from chronic MI and identification of acute myocarditis. On the basis of the currently available data; however, we conclude that T2-weighted MR imaging should not be used to delineate the area at risk in patients with ischemic myocardial injury.

Disclosures of Potential Conflicts of Interest:

P.C. Financial activities related to the present article: none to disclose. Financial activities not related to the present article: is a consultant to Guerbet; performed lectures for Novartis and Siemens. Other relationships: none to disclose. **H.W.K.** No potential conflicts of interest to disclose. **R.J.K.** No potential conflicts of interest to disclose.

References

1. Reimer KA, Jennings RB. The "wavefront phenomenon" of myocardial ischemic cell death. II. Transmural progression of necrosis within the framework of ischemic bed size (myocardium at risk) and collateral flow. *Lab Invest* 1979;40(6):633-644.
2. Eagle KA, Nallamothu BK, Mehta RH, et al. Trends in acute reperfusion therapy for ST-segment elevation myocardial infarction from 1999 to 2006: we are getting better but we have got a long way to go. *Eur Heart J* 2008;29(5):609-617.
3. Lee JT, Ideker RE, Reimer KA. Myocardial infarct size and location in relation to the coronary vascular bed at risk in man. *Circulation* 1981;64(3):526-534.
4. <http://scholar.google.com/>. Accessed August 15, 2011.
5. Friedrich MG. Myocardial edema: a new clinical entity? *Nat Rev Cardiol* 2010;7(5):292-296.
6. ClinicalTrials.gov Web site. <http://clinicaltrials.gov/>. Accessed August 15, 2011.
7. Current Controlled Trials Web site. <http://www.controlled-trials.com/>. Accessed August 15, 2011.
8. García-Dorado D, Oliveras J, Gili J, et al. Analysis of myocardial oedema by magnetic resonance imaging early after coronary artery occlusion with or without reperfusion. *Cardiovasc Res* 1993;27(8):1462-1469.
9. Aletras AH, Tilak GS, Natanzon A, et al. Retrospective determination of the area at risk for reperfused acute myocardial infarction with T2-weighted cardiac magnetic resonance imaging: histopathological and displacement encoding with stimulated echoes (DENSE) functional validations. *Circulation* 2006;113(15):1865-1870.
10. Reimer KA, Jennings RB. The changing anatomic reference base of evolving myocardial infarction: underestimation of myocardial collateral blood flow and overestimation of experimental anatomic infarct size due to tissue edema, hemorrhage and acute inflammation. *Circulation* 1979;60(4):866-876.
11. Tilak GS, Hsu LY, Hoyt RF Jr, Arai AE, Aletras AH. In vivo T2-weighted magnetic resonance imaging can accurately determine the ischemic area at risk for 2-day-old nonreperfused myocardial infarction. *Invest Radiol* 2008;43(1):7-15.
12. Kim RJ, Fieno DS, Parrish TB, et al. Relationship of MRI delayed contrast enhancement to irreversible injury, infarct age, and contractile function. *Circulation* 1999;100(19):1992-2002.
13. Fieno DS, Kim RJ, Chen EL, Lomasney JW, Klocke FJ, Judd RM. Contrast-enhanced magnetic resonance imaging of myocardium at risk: distinction between reversible and irreversible injury throughout infarct healing. *J Am Coll Cardiol* 2000;36(6):1985-1991.
14. Schelbert EB, Hsu LY, Anderson SA, et al. Late gadolinium-enhancement cardiac magnetic resonance identifies postinfarction myocardial fibrosis and the border zone at the near cellular level in ex vivo rat heart. *Circ Cardiovasc Imaging* 2010;3(6):743-752.
15. Stork A, Lund GK, Muellerleile K, et al. Characterization of the peri-infarction zone using T2-weighted MRI and delayed-enhancement MRI in patients with acute myocardial infarction. *Eur Radiol* 2006;16(10):2350-2357.
16. Choi SI, Jiang CZ, Lim KH, et al. Application of breath-hold T2-weighted, first-pass perfusion and gadolinium-enhanced T1-weighted MR imaging for assessment of myocardial viability in a pig model. *J Magn Reson Imaging* 2000;11(5):476-480.
17. Friedrich MG, Abdel-Aty H, Taylor A, Schulz-Menger J, Messroghli D, Dietz R. The salvaged area at risk in reperfused acute myocardial infarction as visualized by cardiovascular magnetic resonance. *J Am Coll Cardiol* 2008;51(16):1581-1587.
18. Wright J, Adriaenssens T, Dymarkowski S, Desmet W, Bogaert J. Quantification of myocardial area at risk with T2-weighted CMR: comparison with contrast-enhanced CMR and coronary angiography. *JACC Cardiovasc Imaging* 2009;2(7):825-831.
19. Wince WB, Kim RJ. Molecular imaging: T2-weighted CMR of the area at risk—a risky business? *Nat Rev Cardiol* 2010;7(10):547-549.
20. Johnston DL, Brady TJ, Ratner AV, et al. Assessment of myocardial ischemia with proton magnetic resonance: effects of a three hour coronary occlusion with and without reperfusion. *Circulation* 1985;71(3):595-601.
21. Miller DD, Johnston DL, Dragotakes D, et al. Effect of hyperosmotic mannitol on magnetic resonance relaxation parameters in reperfused canine myocardial infarction. *Magn Reson Imaging* 1989;7(1):79-88.
22. Ryan T, Tarver RD, Duerk JL, Sawada SG, Hollenkamp NC. Distinguishing viable from infarcted myocardium after experimental ischemia and reperfusion by using nuclear magnetic resonance imaging. *J Am Coll Cardiol* 1990;15(6):1355-1364.
23. Higgins CB, Herfkens R, Lipton MJ, et al. Nuclear magnetic resonance imaging of acute myocardial infarction in dogs: alterations in magnetic relaxation times. *Am J Cardiol* 1983;52(1):184-188.
24. Buxt LM, Hsu D, Katz J, et al. Estimation of myocardial water content using transverse relaxation time from dual spin-echo magnetic resonance imaging. *Magn Reson Imaging* 1993;11(3):375-383.
25. Whalen DA Jr, Hamilton DG, Ganote CE, Jennings RB. Effect of a transient period of ischemia on myocardial cells. I. Effects on cell volume regulation. *Am J Pathol* 1974;74(3):381-397.
26. Jennings RB, Schaper J, Hill ML, Steenbergen C Jr, Reimer KA. Effect of reperfusion late in the phase of reversible ischemic injury: changes in cell volume, electrolytes, metabolites, and ultrastructure. *Circ Res* 1985;56(2):262-278.
27. Jennings RB, Murry C, Reimer KA. Myocardial effects of brief periods of ischemia followed by reperfusion. *Adv Cardiol* 1990;37:7-31.
28. Haendchen RV, Corday E, Torres M, Maurer G, Fishbein MC, Meerbaum S. Increased regional end-diastolic wall thickness early after reperfusion: a sign of irreversibly damaged myocardium. *J Am Coll Cardiol* 1984;3(6):1444-1453.
29. Murphy ML, Peng CF, Kane JJ Jr, Straub KD. Ventricular performance and biochemical alteration of regional ischemic myocardium after reperfusion in the pig. *Am J Cardiol* 1982;50(4):821-828.
30. Turschner O, D'hooge J, Dommke C, et al. The sequential changes in myocardial thickness and thickening which occur during acute transmural infarction, infarct reperfusion and the resultant expression of reperfusion injury. *Eur Heart J* 2004;25(9):794-803.
31. Eitel I, Friedrich MG. T2-weighted cardiovascular magnetic resonance in acute cardiac disease. *J Cardiovasc Magn Reson* 2011;13:13.
32. Powell WJ Jr, DiBona DR, Flores J, Leaf A. The protective effect of hyperosmotic mannitol in myocardial ischemia and necrosis. *Circulation* 1976;54(4):603-615.
33. Kloner RA, Rude RE, Carlson N, Maroko PR, DeBoer LW, Braunwald E. Ultrastructural evidence of microvascular damage and myocardial cell injury after coronary artery occlusion: which comes first? *Circulation* 1980;62(5):945-952.
34. Friedrich MG, Kim HW, Kim RJ. T2-weighted imaging to assess post-infarct myocardium at risk. *JACC Cardiovasc Imaging* 2011;4(9):1014-1021.
35. Jacobson B, Anderson WA, Arnold JT. A proton magnetic resonance study of the hy-

- dration of deoxyribonucleic acid. *Nature* 1954;173:772-773.
36. Klotz IM. Protein hydration and behavior; many aspects of protein behavior can be interpreted in terms of frozen water of hydration. *Science* 1958;128(3328):815-822.
 37. Hazlewood CF, Chang DC, Nichols BL, Woessner DE. Nuclear magnetic resonance transverse relaxation times of water protons in skeletal muscle. *Biophys J* 1974; 14(8):583-606.
 38. Hallenga K, Koenig SH. Protein rotational relaxation as studied by solvent 1H and 2H magnetic relaxation. *Biochemistry* 1976;15(19):4255-4264.
 39. Halle B. Protein hydration dynamics in solution: a critical survey. *Philos Trans R Soc Lond B Biol Sci* 2004;359(1448):1207-1223; discussion 1223-1224, 1323-1328.
 40. Henchman RH, McCammon JA. Structural and dynamic properties of water around acetylcholinesterase. *Protein Sci* 2002; 11(9):2080-2090.
 41. Otting G, Liepinsh E, Wüthrich K. Protein hydration in aqueous solution. *Science* 1991; 254(5034):974-980.
 42. Denisov VP, Halle B. Protein hydration dynamics in aqueous solution: a comparison of bovine pancreatic trypsin inhibitor and ubiquitin by oxygen-17 spin relaxation dispersion. *J Mol Biol* 1995;245(5):682-697.
 43. Chen EL, Kim RJ. Magnetic resonance water proton relaxation in protein solutions and tissue: T(1rho) dispersion characterization. *PLoS ONE* 2010;5(1):e8565.
 44. Kloner RA, Ganote CE, Whalen DA Jr, Jennings RB. Effect of a transient period of ischemia on myocardial cells. II. Fine structure during the first few minutes of reflow. *Am J Pathol* 1974;74(3):399-422.
 45. Jennings RB, Sommers HM, Kaltenbach JP, West JJ. Electrolyte alterations in acute myocardial ischemic injury. *Circ Res* 1964; 14:260-269.
 46. Rehwald WG, Fieno DS, Chen EL, Kim RJ, Judd RM. Myocardial magnetic resonance imaging contrast agent concentrations after reversible and irreversible ischemic injury. *Circulation* 2002;105(2):224-229.
 47. Kim RJ, Judd RM, Chen EL, Fieno DS, Parrish TB, Lima JA. Relationship of elevated 23Na magnetic resonance image intensity to infarct size after acute reperfused myocardial infarction. *Circulation* 1999; 100(2):185-192.
 48. Kim RJ, Lima JA, Chen EL, et al. Fast 23Na magnetic resonance imaging of acute reperfused myocardial infarction: potential to assess myocardial viability. *Circulation* 1997;95(7):1877-1885.
 49. Yellon DM, Hausenloy DJ. Myocardial reperfusion injury. *N Engl J Med* 2007; 357(11):1121-1135.
 50. Lotan CS, Miller SK, Cranney GB, Pohost GM, Elgavish GA. The effect of postinfarction intramyocardial hemorrhage on transverse relaxation time. *Magn Reson Med* 1992;23(2):346-355.
 51. Mikami Y, Sakuma H, Nagata M, et al. Relation between signal intensity on T2-weighted MR images and presence of microvascular obstruction in patients with acute myocardial infarction. *AJR Am J Roentgenol* 2009;193(4):W321-W326.
 52. O'Regan DP, Ahmed R, Karunanithy N, et al. Reperfusion hemorrhage following acute myocardial infarction: assessment with T2* mapping and effect on measuring the area at risk. *Radiology* 2009;250(3):916-922.
 53. Zhao ZQ, Corvera JS, Halkos ME, et al. Inhibition of myocardial injury by ischemic preconditioning during reperfusion: comparison with ischemic preconditioning. *Am J Physiol Heart Circ Physiol* 2003;285(2): H579-H588.
 54. Staat P, Rioufol G, Piot C, et al. Postconditioning the human heart. *Circulation* 2005; 112(14):2143-2148.
 55. Piot C, Croisille P, Staat P, et al. Effect of cyclosporine on reperfusion injury in acute myocardial infarction. *N Engl J Med* 2008; 359(5):473-481.
 56. Braunwald E. Clinical efforts to reduce myocardial infarct size: the next step. *J Cardiovasc Pharmacol Ther* 2011;16(3-4):349-353.
 57. Hausenloy DJ, Yellon DM. Clinical translation of cardioprotective strategies: report and recommendations of the Hatter Institute 5th International Workshop on Cardioprotection. *Basic Res Cardiol* 2008;103(5): 493-500.
 58. Kellman P, Aletras AH, Mancini C, McVeigh ER, Arai AE. T2-prepared SSFP improves diagnostic confidence in edema imaging in acute myocardial infarction compared to turbo spin echo. *Magn Reson Med* 2007; 57(5):891-897.
 59. Verhaert D, Thavendiranathan P, Giri S, et al. Direct T2 quantification of myocardial edema in acute ischemic injury. *JACC Cardiovasc Imaging* 2011;4(3):269-278.
 60. Viallon M, Mewton N, Stemmer A, et al. T2-weighted cardiac MR assessment of the myocardial area-at-risk and salvage area in acute reperfused myocardial infarction: comparison of state-of-the-art dark blood and bright blood T2-weighted sequences. *J Magn Reson Imaging* 2012;35(2): 328-339.
 61. Simonetti OP, Kim RJ, Fieno DS, et al. An improved MR imaging technique for the visualization of myocardial infarction. *Radiology* 2001;218(1):215-223.
 62. Kim RJ, Shah DJ, Judd RM. How we perform delayed enhancement imaging. *J Cardiovasc Magn Reson* 2003;5(3):505-514.
 63. Kellman P, Arai AE, McVeigh ER, Aletras AH. Phase-sensitive inversion recovery for detecting myocardial infarction using gadolinium-delayed hyperenhancement. *Magn Reson Med* 2002;47(2):372-383.
 64. Eitel I, Desch S, Fuernau G, et al. Prognostic significance and determinants of myocardial salvage assessed by cardiovascular magnetic resonance in acute reperfused myocardial infarction. *J Am Coll Cardiol* 2010;55(22):2470-2479.
 65. Kim HW, Farzaneh-Far A, Kim RJ. Cardiovascular magnetic resonance in patients with myocardial infarction: current and emerging applications. *J Am Coll Cardiol* 2009; 55(1):1-16.
 66. Flett AS, Hasleton J, Cook C, et al. Evaluation of techniques for the quantification of myocardial scar of differing etiology using cardiac magnetic resonance. *JACC Cardiovasc Imaging* 2011;4(2):150-156.
 67. Arai AE. Magnetic resonance imaging for area at risk, myocardial infarction, and myocardial salvage. *J Cardiovasc Pharmacol Ther* 2011;16(3-4):313-320.
 68. Matsumoto H, Matsuda T, Miyamoto K, Shimada T, Mikuri M, Hiraoka Y. Perinfarct zone on early contrast-enhanced CMR imaging in patients with acute myocardial infarction. *JACC Cardiovasc Imaging* 2011;4(6):610-618.
 69. Berry C, Kellman P, Mancini C, et al. Magnetic resonance imaging delineates the ischemic area at risk and myocardial salvage in patients with acute myocardial infarction. *Circ Cardiovasc Imaging* 2010;3(5): 527-535.
 70. Yellon DM, Hearse DJ, Crome R, Wyse RK. Temporal and spatial characteristics of evolving cell injury during regional myocardial ischemia in the dog: the "border zone" controversy. *J Am Coll Cardiol* 1983;2(4):661-670.
 71. Axford-Gatley RA, Wilson GJ. The "border zone" in myocardial infarction: an ultrastructural study in the dog using an electron-dense blood flow marker. *Am J Pathol* 1988;131(3):452-464.
 72. Okun EM, Factor SM, Kirk ES. End-capillary loops in the heart: an explanation for discrete myocardial infarctions without border zones. *Science* 1979;206(4418):565-567.
 73. Factor SM, Okun EM, Minase T, Kirk ES. The microcirculation of the human heart: end-capillary loops with discrete perfusion fields. *Circulation* 1982;66(6):1241-1248.
 74. Saeed M, Lund G, Wendland MF, Bremerich J, Weinmann H, Higgins CB. Magnetic resonance characterization of the peri-infarction zone of reperfused myocardial infarction with necrosis-specific and extracellular nonspecific contrast media. *Circulation* 2001;103(6):871-876.
 75. Oshinski JN, Yang Z, Jones JR, Mata JF, French BA. Imaging time after Gd-DTPA injection is critical in using delayed enhancement to determine infarct size accurately with magnetic resonance imaging. *Circulation* 2001;104(23):2838-2842.